

The Pharynx

Fred G.
Fedok, MD
FACS

Facial Plastic and
Reconstructive
Surgery

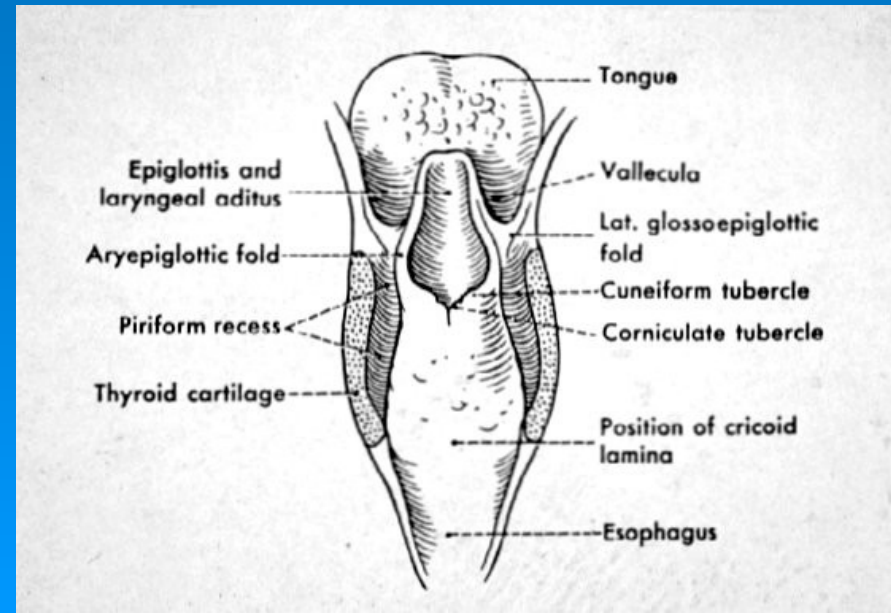
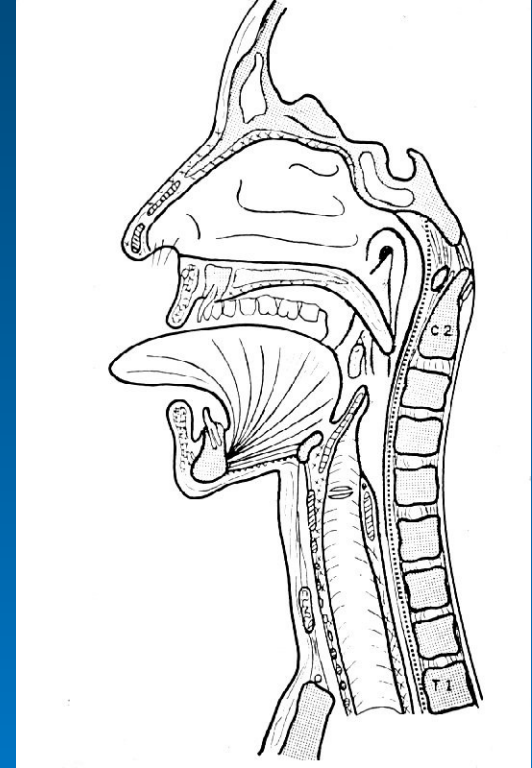


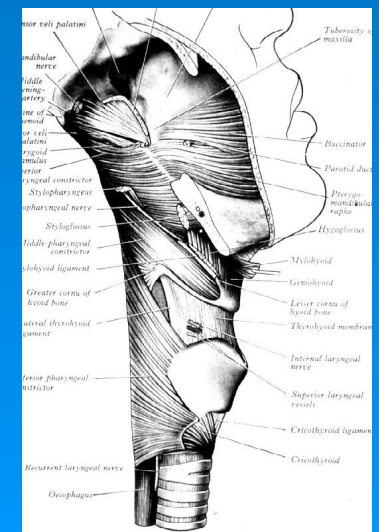
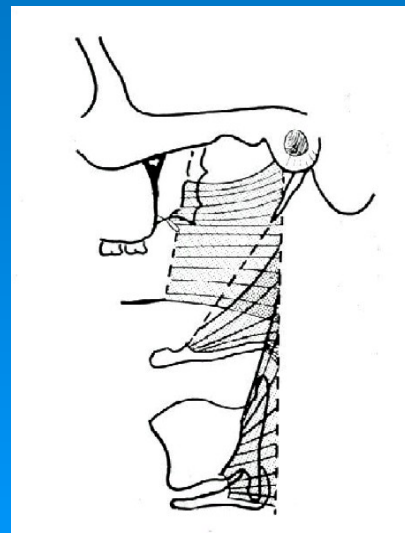
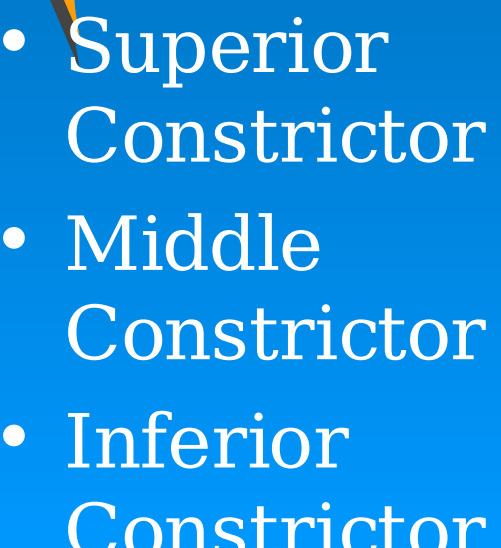

The Pharynx

- What Is It?
- What Does It Do ?
- How Does It Work?
- What Kind Of Things Can Go Wrong With It?

- Nasopharynx
 - Posterior Choanae To Soft Palate
- Oropharynx
 - Larynx – Vallate Papilla
 - Soft Palate
- Hypopharynx
 - Posterior Larynx - Esophagus



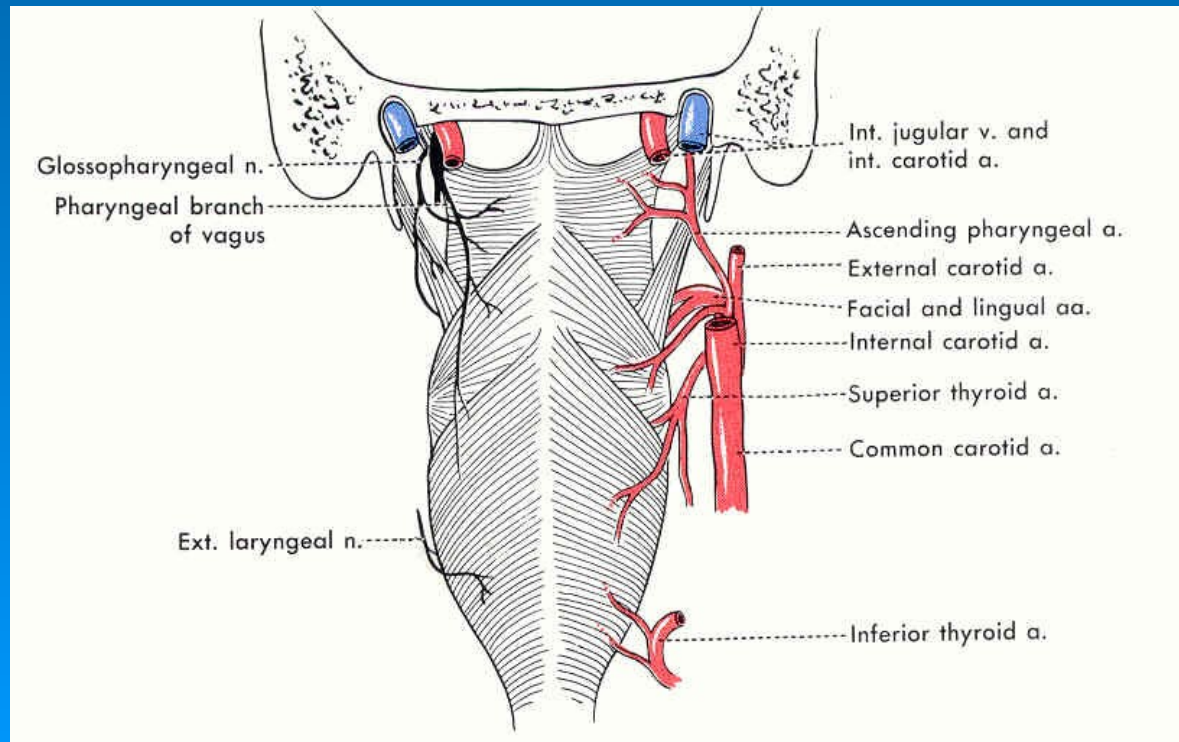


- Pharynx – Arteries

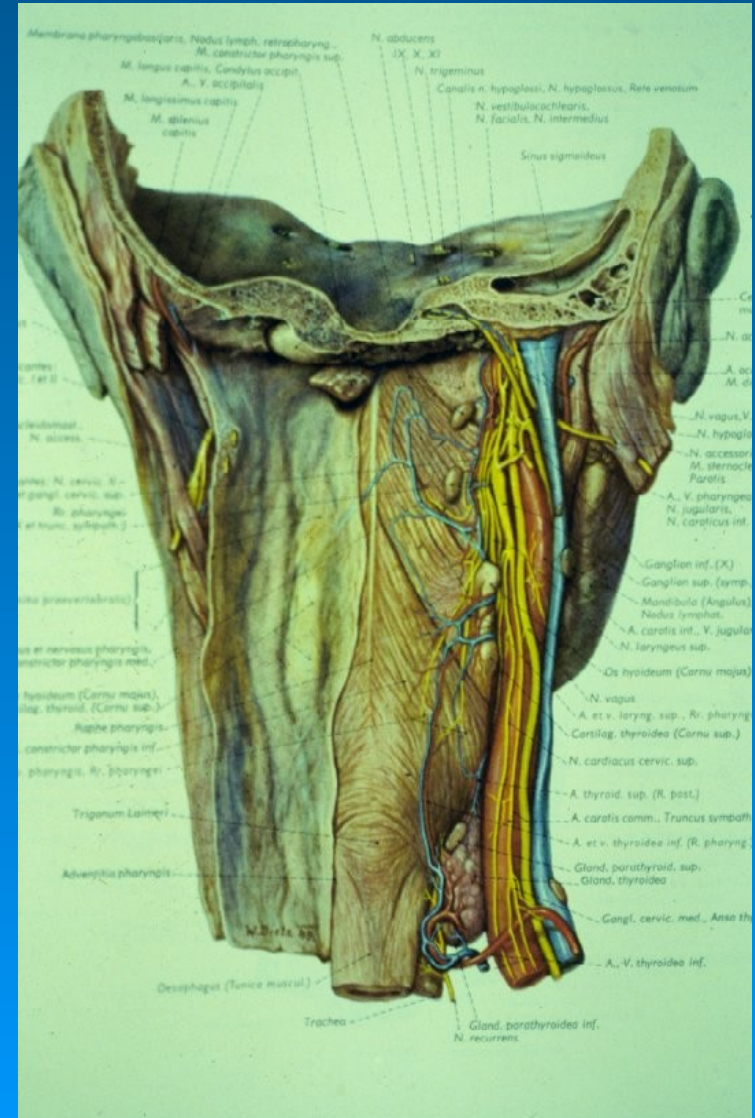- Ascending Pharyngeal Artery
- Palatine Arteries
- Thyroid Arteries

- Pharyngeal – Veins

- Pharyngeal Plexus
- S And I Thyroid Veins

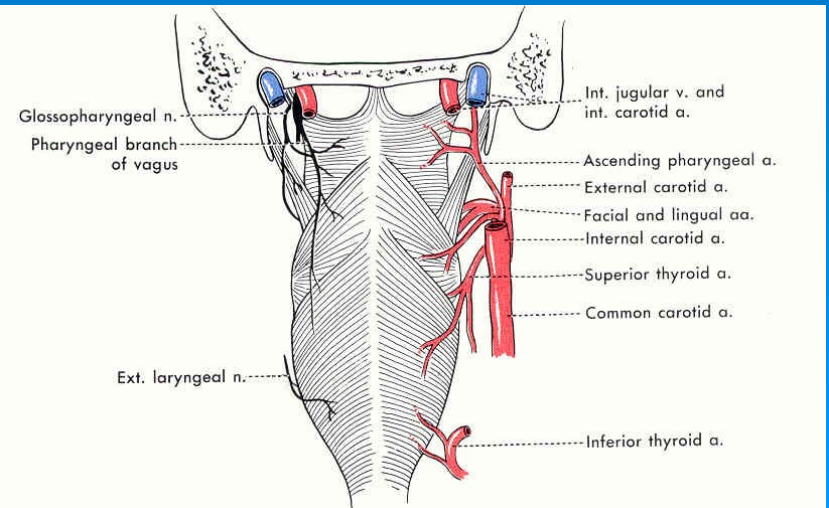
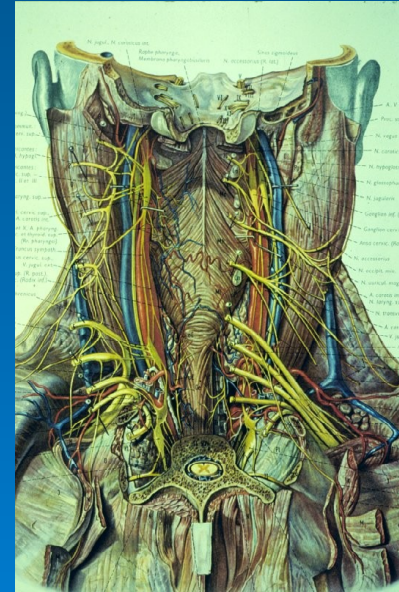


- Retropharyngeal Lymph Nodes



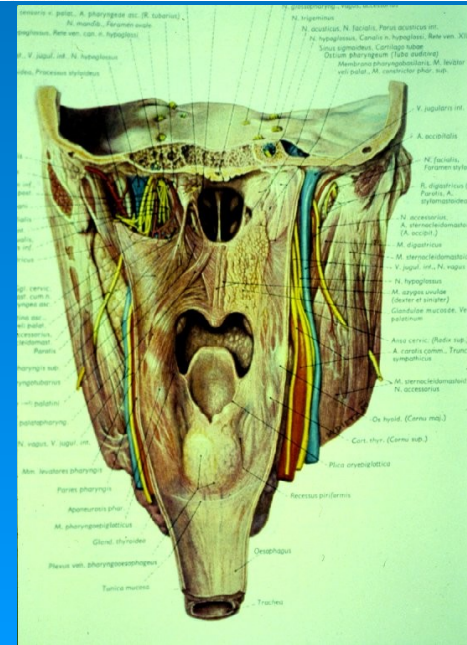
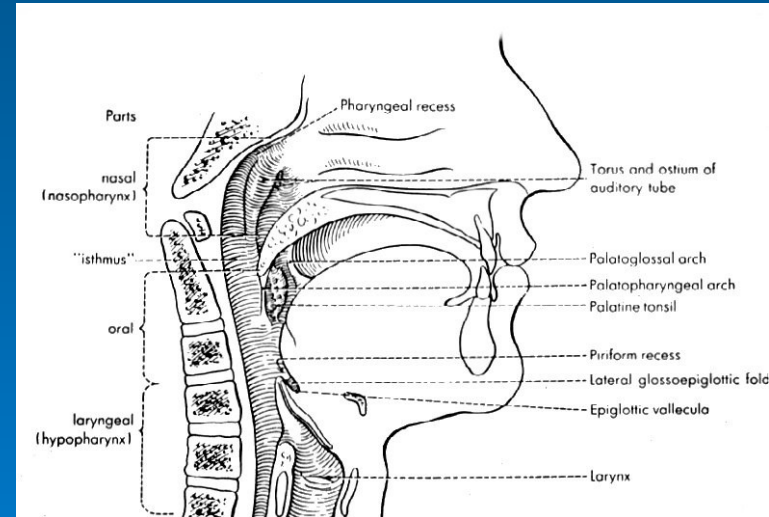
Pharynx - Nerves

- Pharyngeal Plexus
- Glossopharyngeal
- Vagus



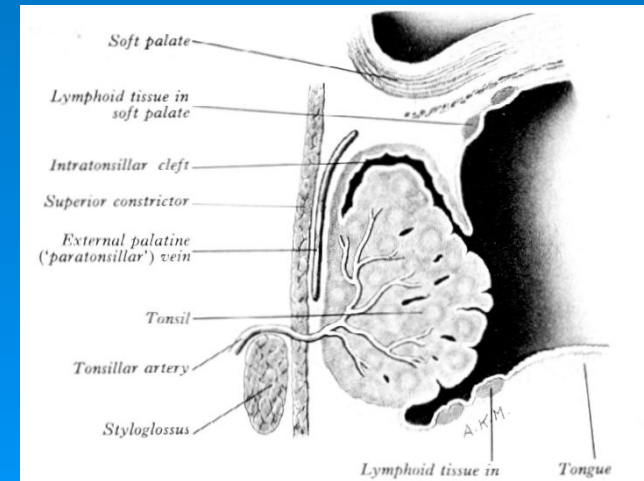
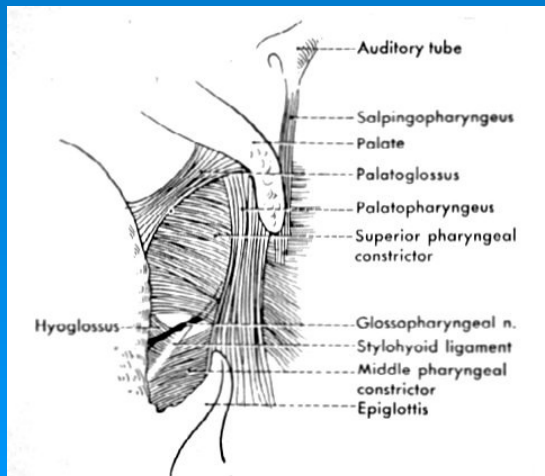
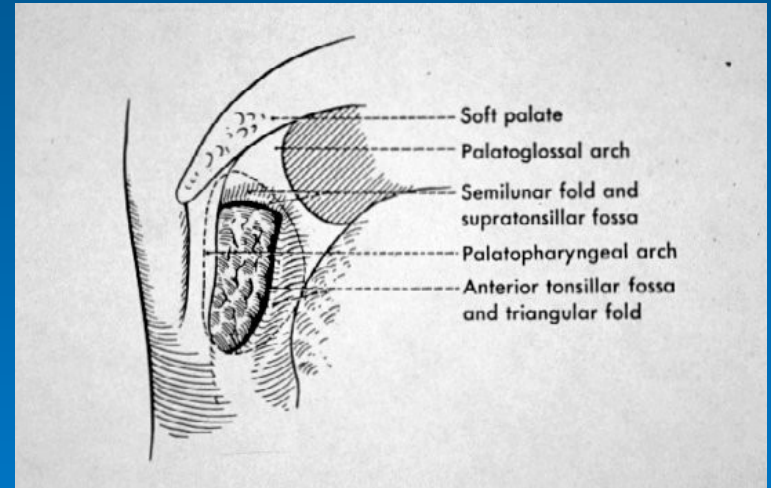
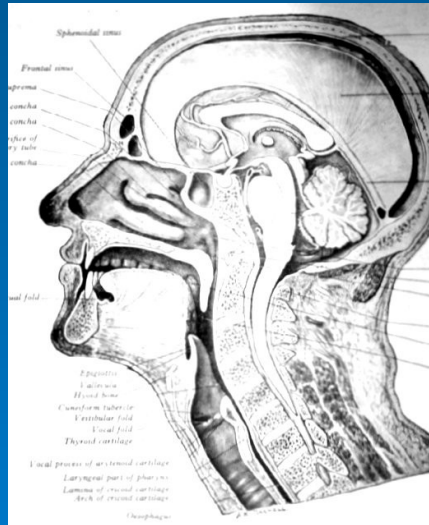
Nasopharynx

- Eustachian Tube
- Adenoids



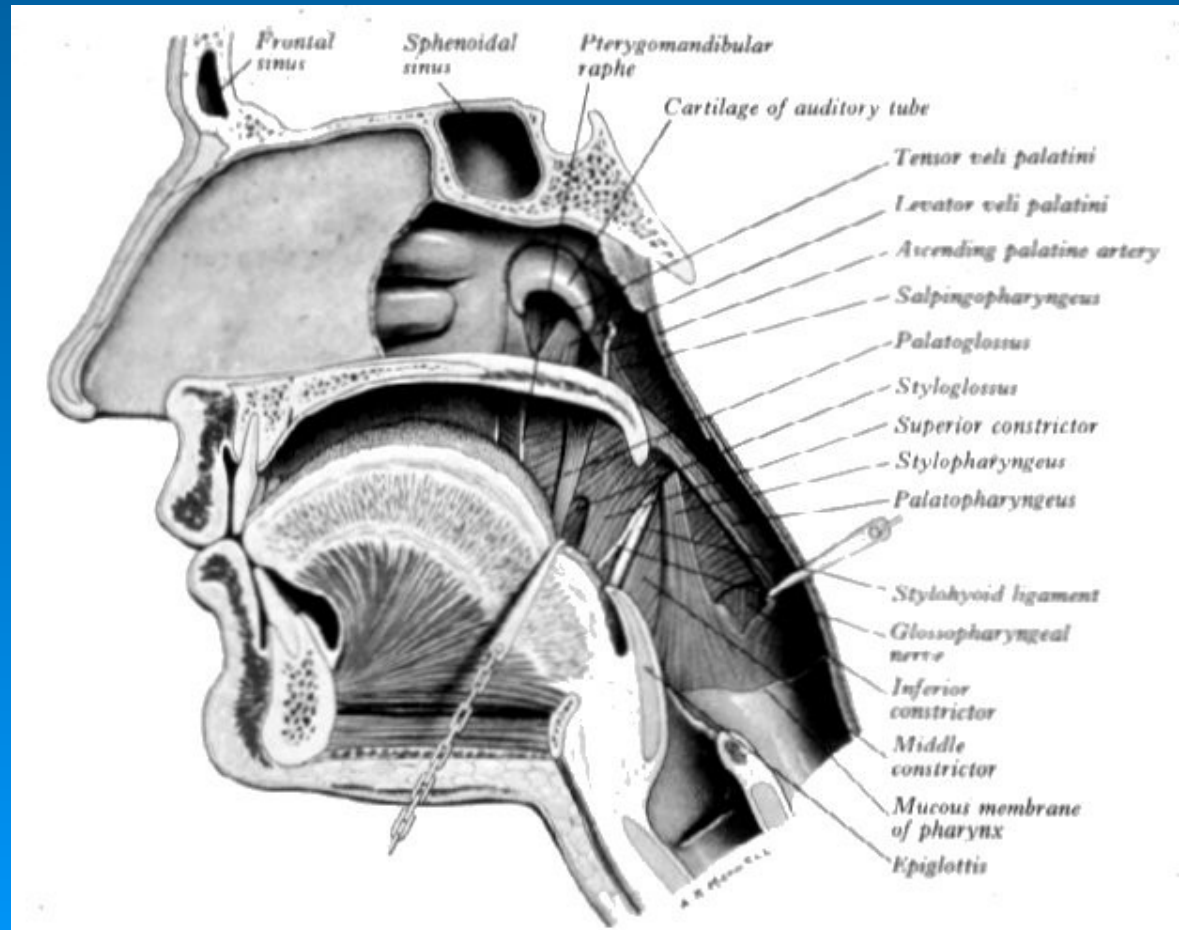
Oropharynx

- Tonsils
- Tongue



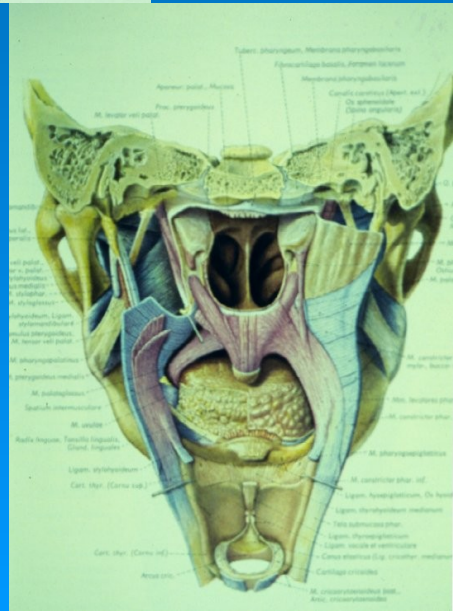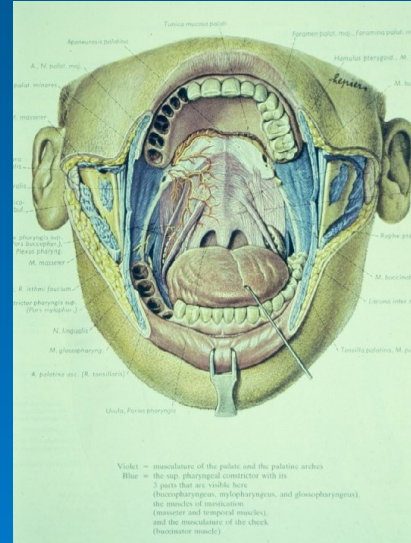
Palate

- Hard
- Soft





- 





Palatal Arteries And Nerves

- Arteries

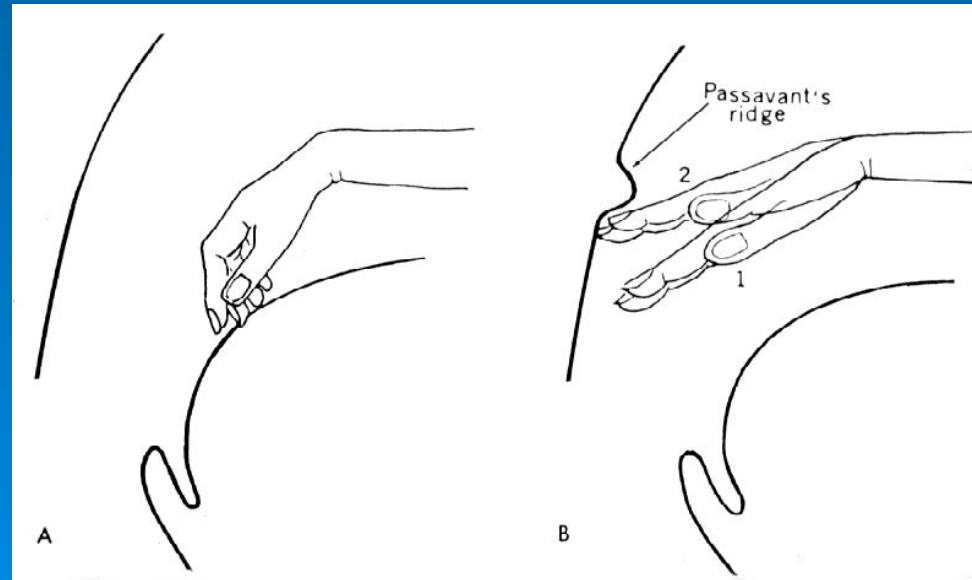
- Descending Palatine Artery
- Greater Palatine Artery
- Lesser Palatine Artery
- Ascending Palatine Branch Of Facial Artery

- Nerves

- Greater Palatine Nerve
- Nasopalatine Nerve
- Lesser Palatine Nerve

Palatal Function

- What Does It Do?
 - Functions In Speech And Swallowing

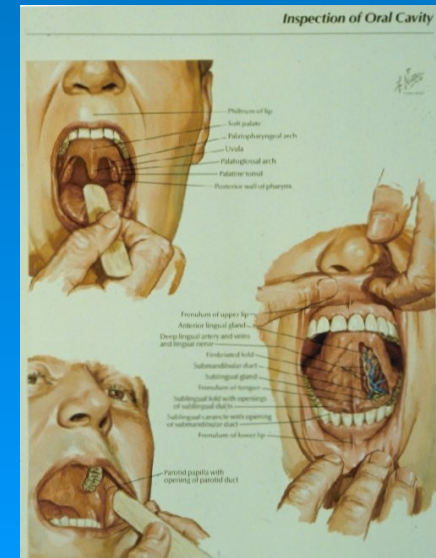
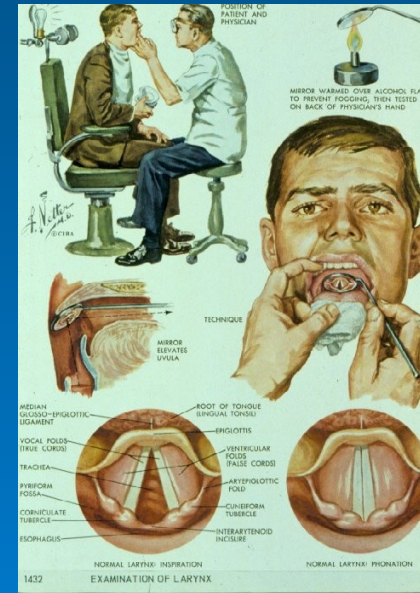


The left side of the slide features two vertical, wavy stripes. The leftmost stripe is light yellow, and the one next to it is a slightly darker shade of yellow. Both stripes have a subtle gradient and a soft shadow effect, giving them a three-dimensional appearance as if they are floating or layered.

What's Important

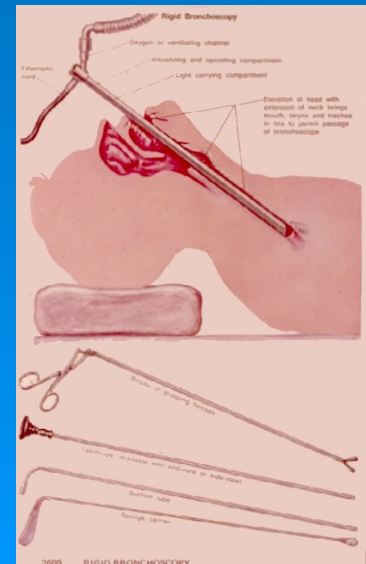
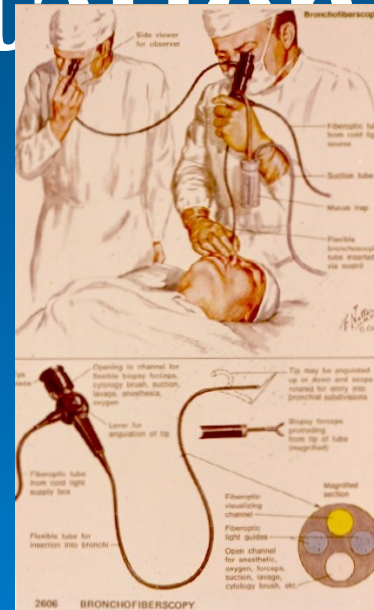
The Examination Of The Upper Aerodigestive Tract

- Can Do A Thorough Examination Of The Nose, Nasopharynx, Oral Cavity, Oropharynx, Hypopharynx With Simply Clinical Tools
 - Mirror
 - Headlight
 - Nasal Speculum
 - Tongue Blade



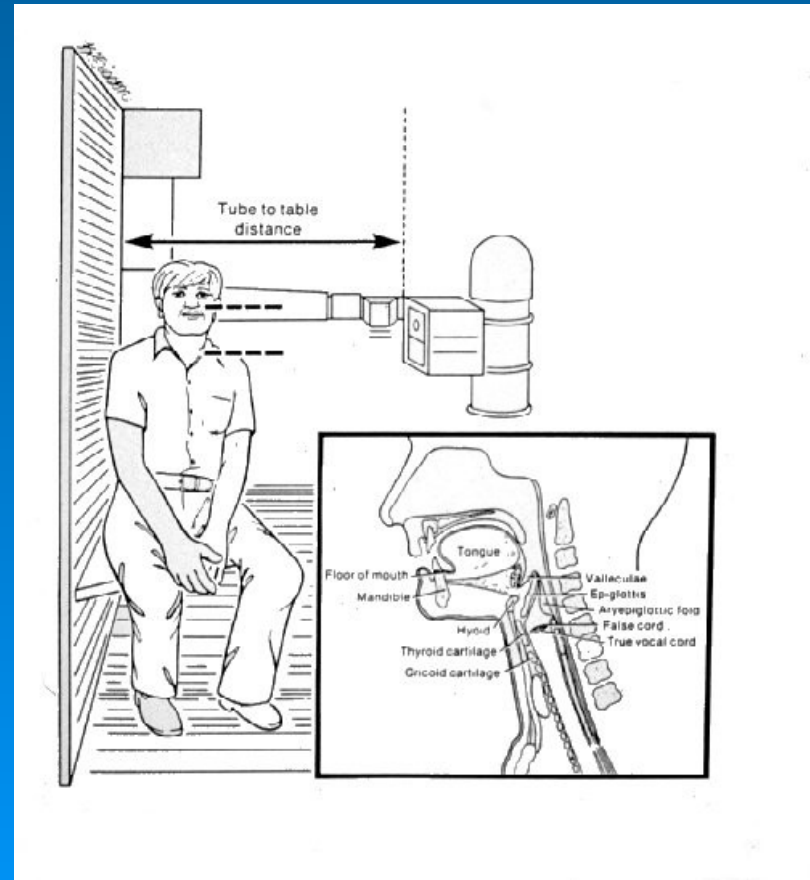
Advanced Instrumentation

- Flexible Laryngoscope / Nasopharyngoscope
- Bronchoscope

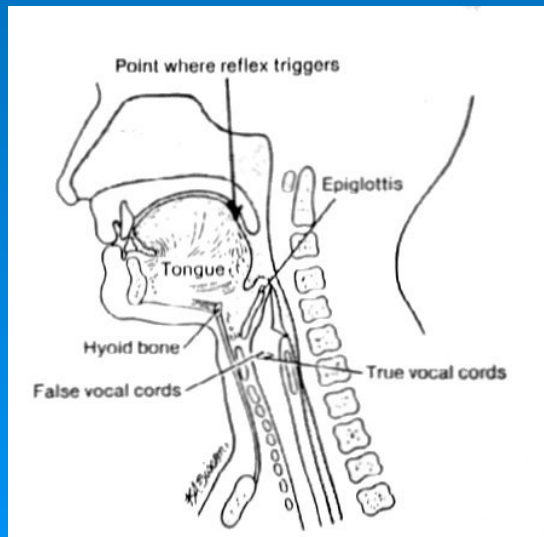
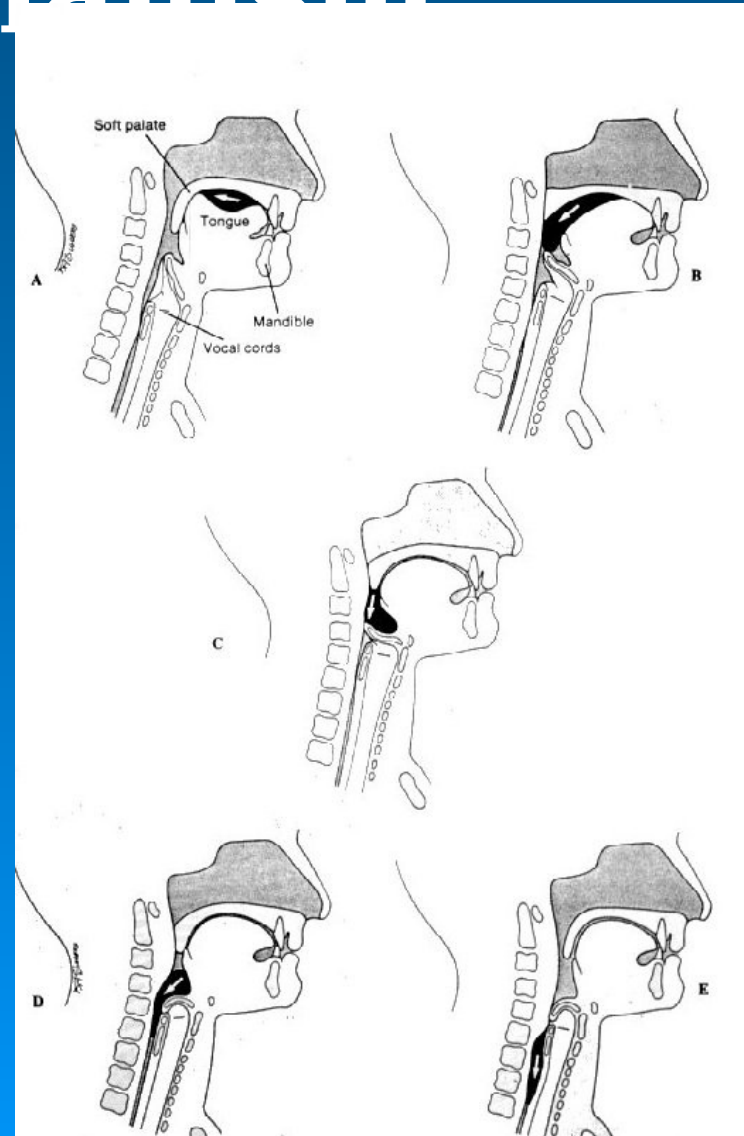
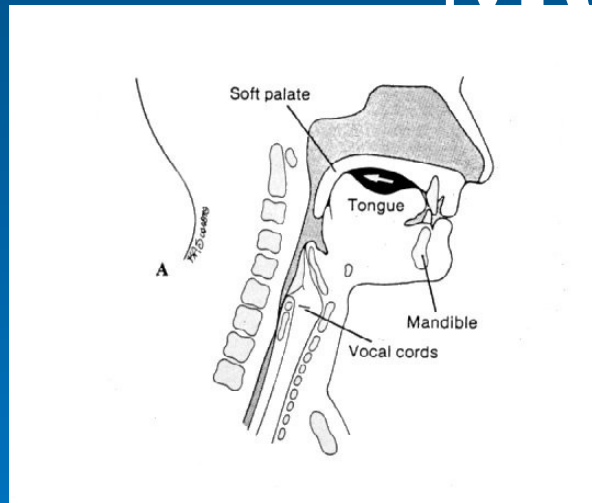


Swallowing Evaluation

- Cinesophagogram
- Barium Swallow
- Rehab Barium Swallow

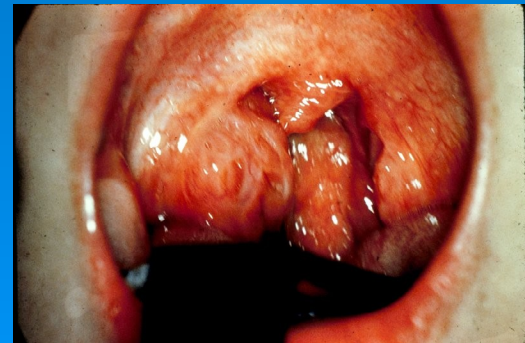
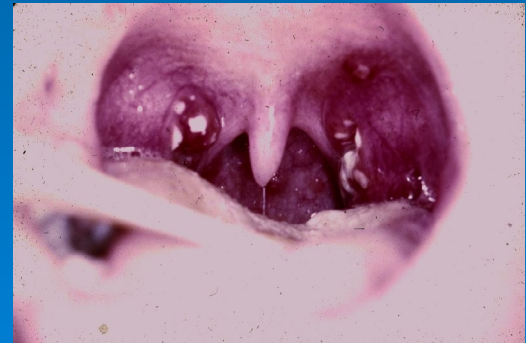
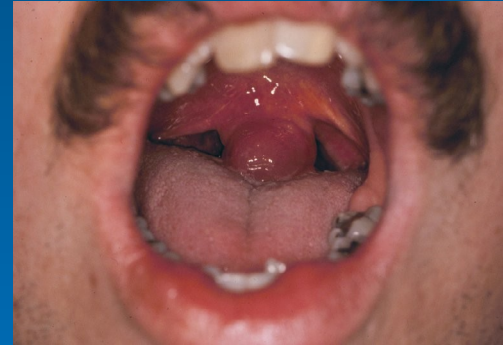The Swallowing Mechanism



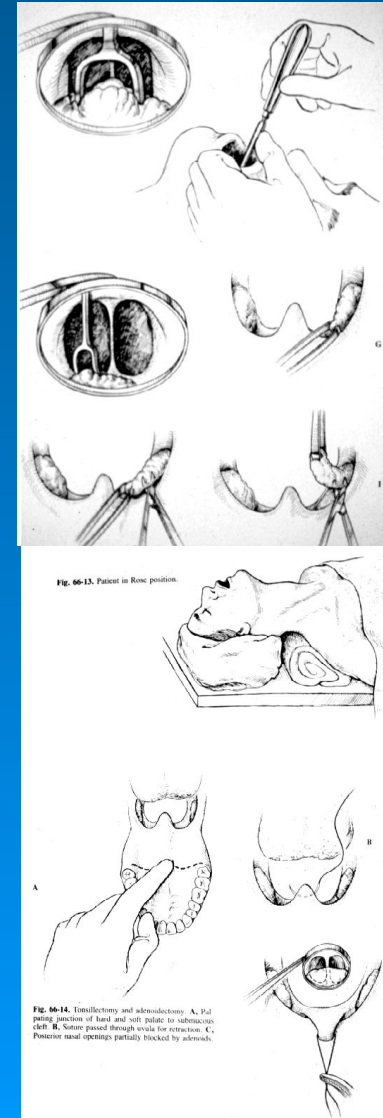
Tonsillitis

- What Is It?
 - Acute
 - Chronic



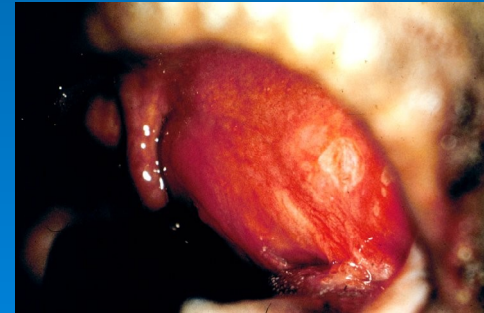The Adenoids

- Part Of Waldeyer's Ring Along With Palatine And Lingual Tonsils



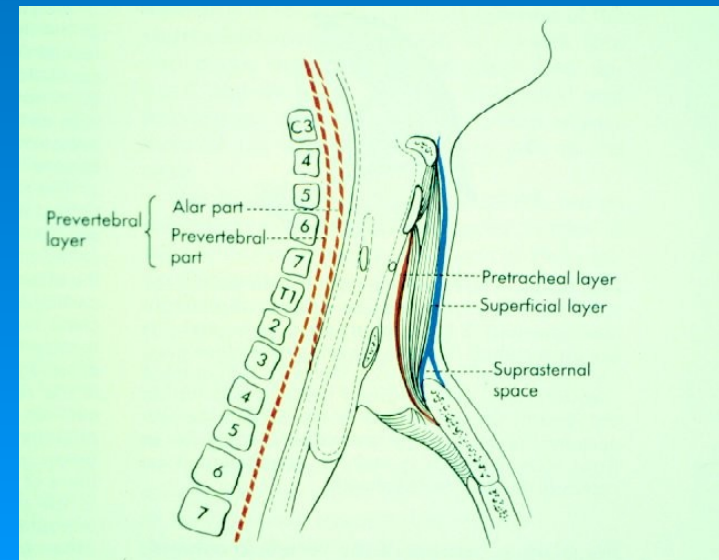
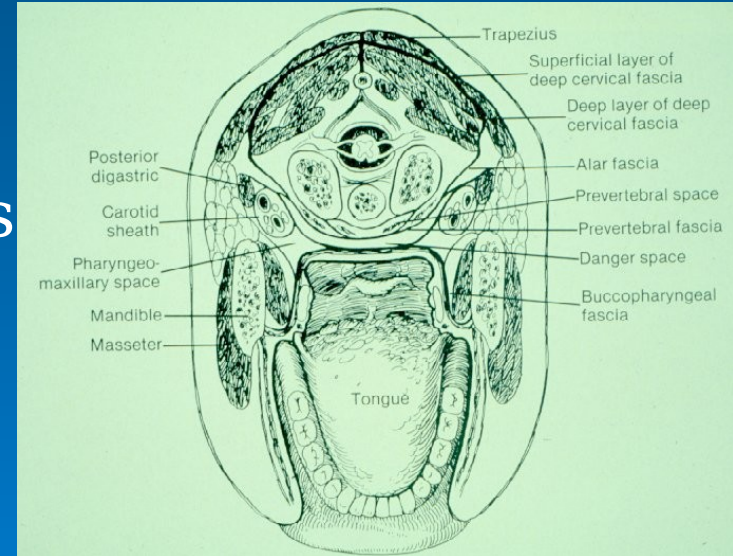
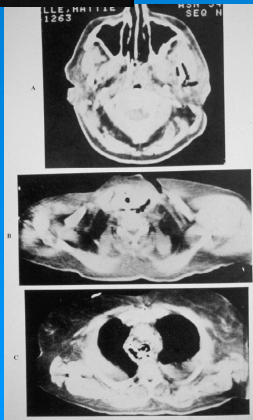
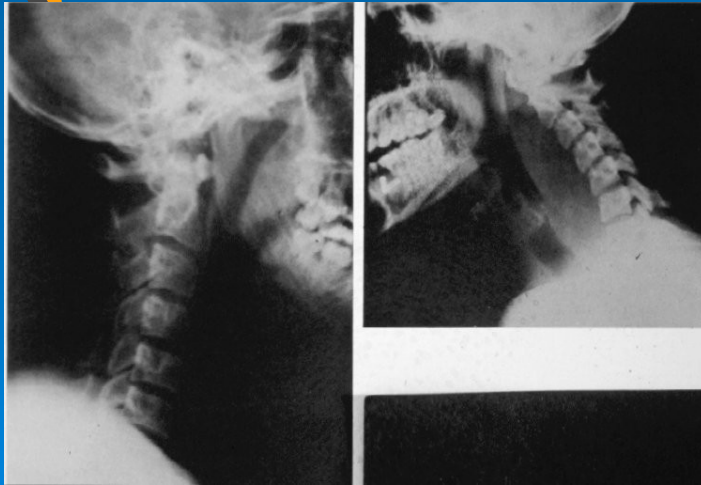
Complications Of Tonsillitis

- Peritonsillar
Abscess



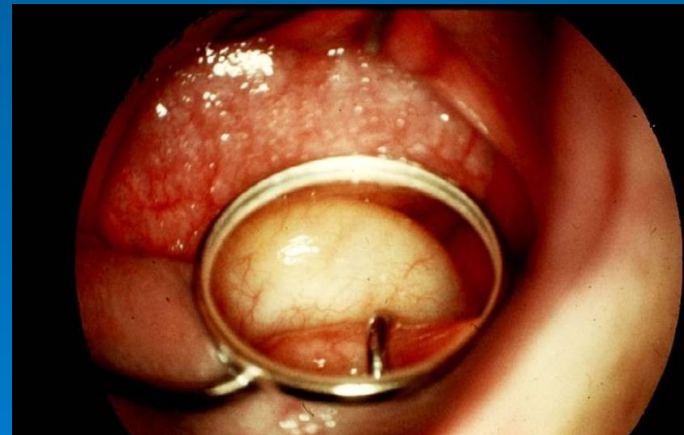Complications Of Tonsillitis

- Deep neck Infections



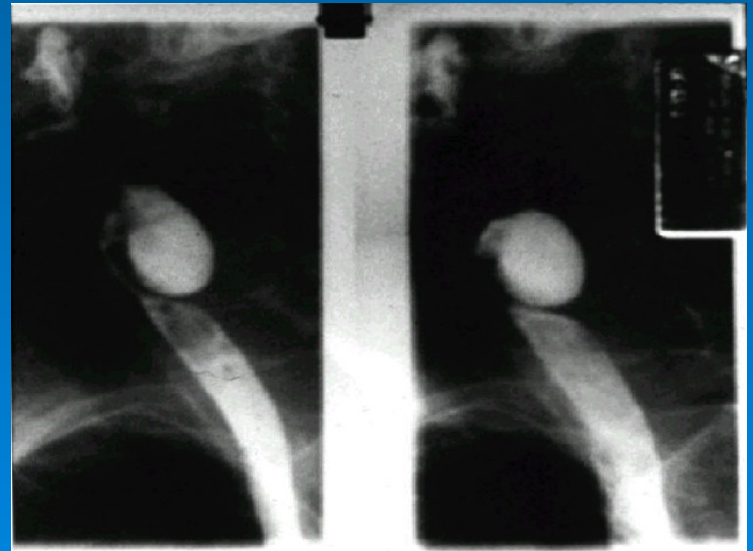
The Pharynx – Other Disorders

- This Originated In The Maxillary Sinus And Presented Hanging Down From Behind The Palate...



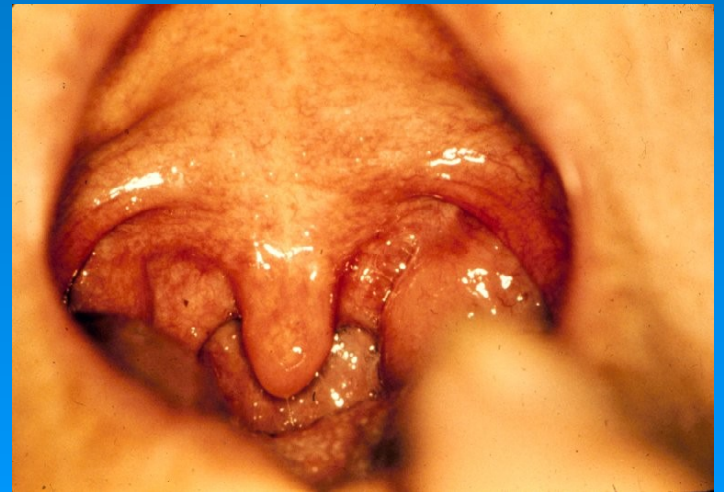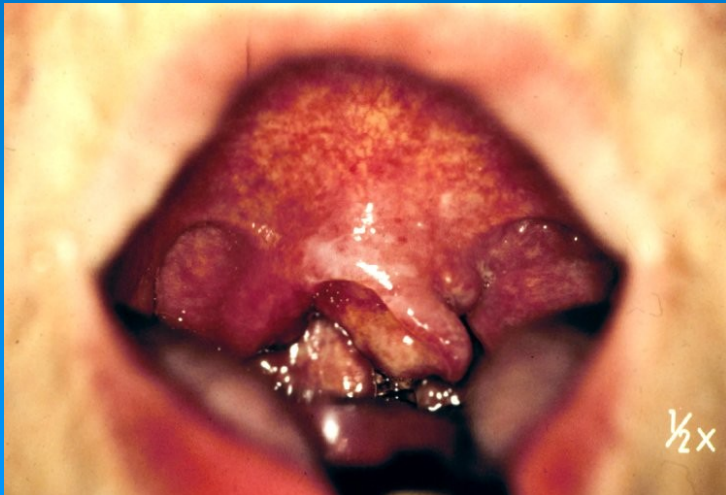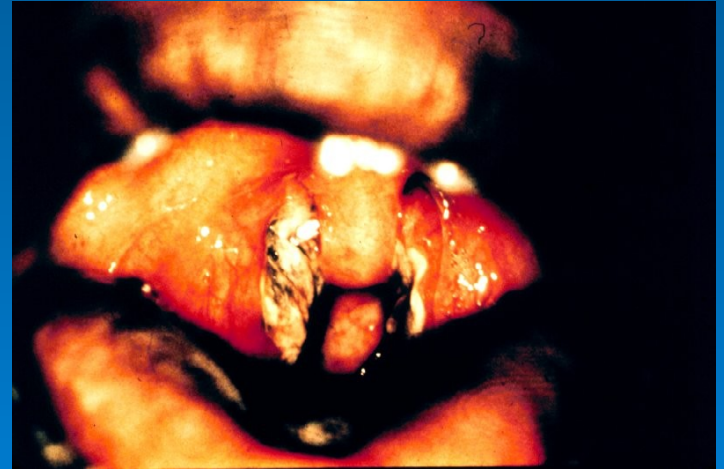The Pharynx – Other Disorders

- This Patient Complains Of Difficulty In Swallowing And Occasionally Regurgitates Undigested Food



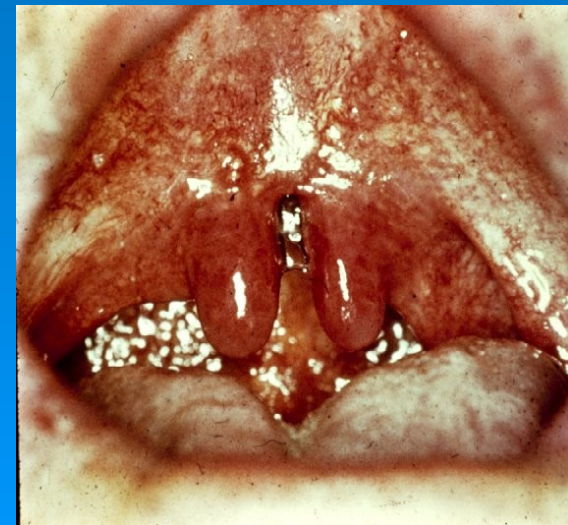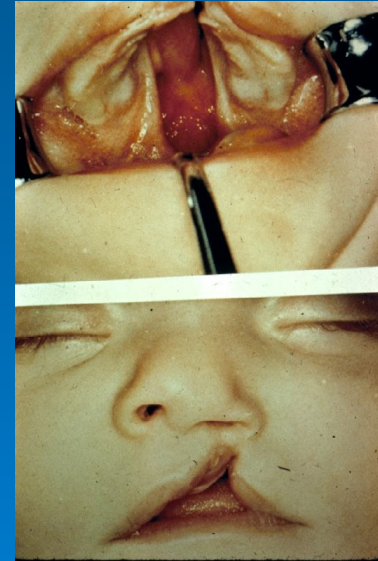The Pharynx – Other Disorders

- These disorders will be treated with surgery, chemotherapy, and/or radiation therapy...



The Pharynx – Other Disorders

- This Patient Will Have Speech And Eating Problems...





The Pharynx

- What Is It?
- What Does It Do ?
- How Does It Work?
- What Kind Of Things Can Go Wrong With It?

The Pharynx

Fred G.
Fedok, MD
FACS

Facial Plastic and
Reconstructive
Surgery

