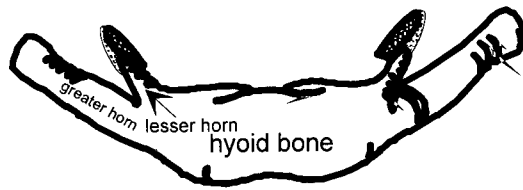
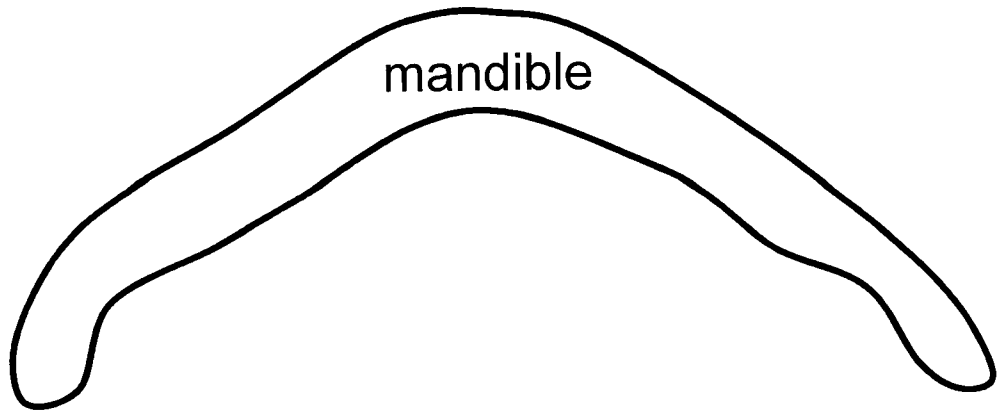
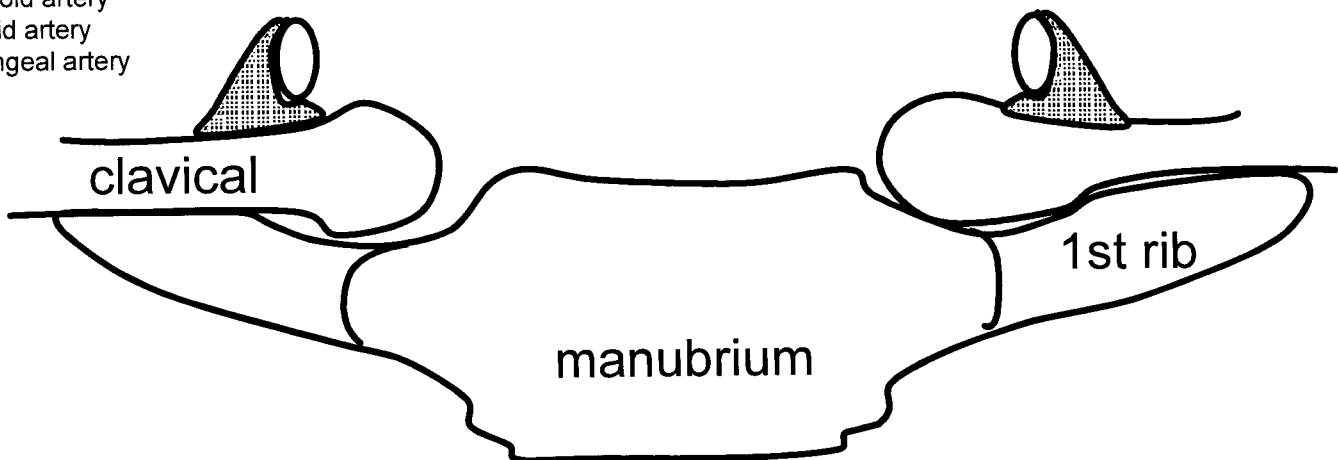
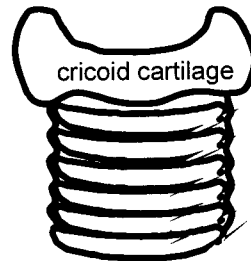
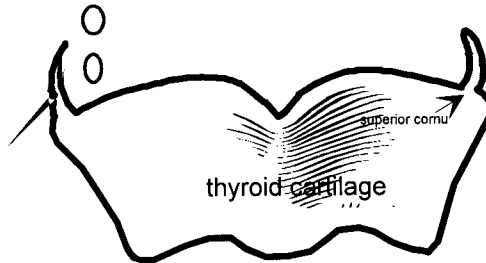


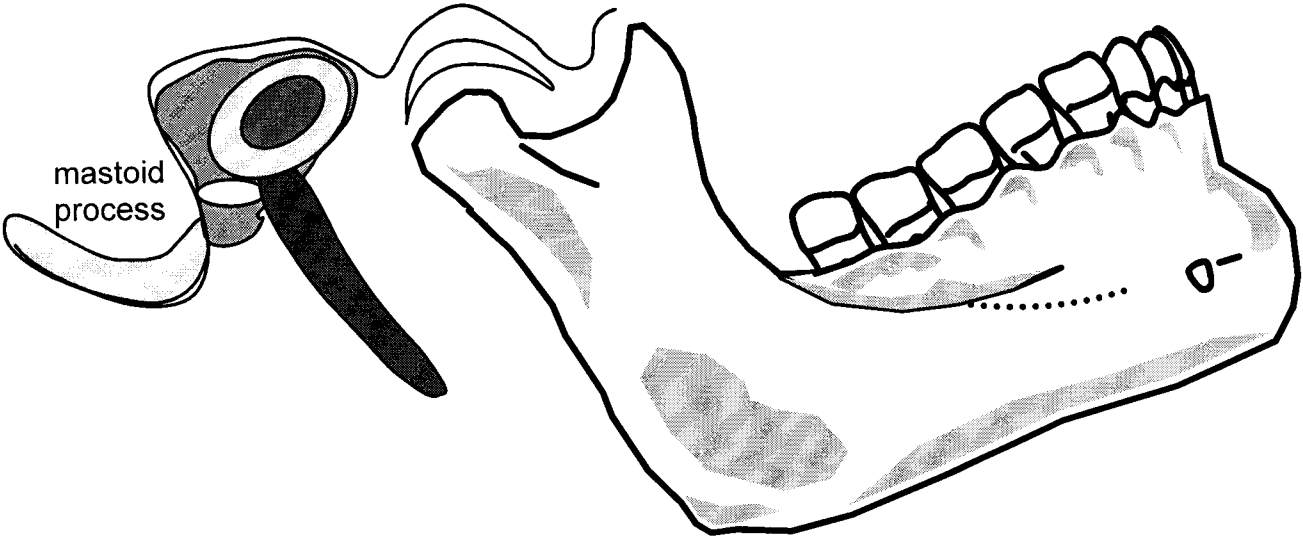
Anterior Triangle - Strap Muscles



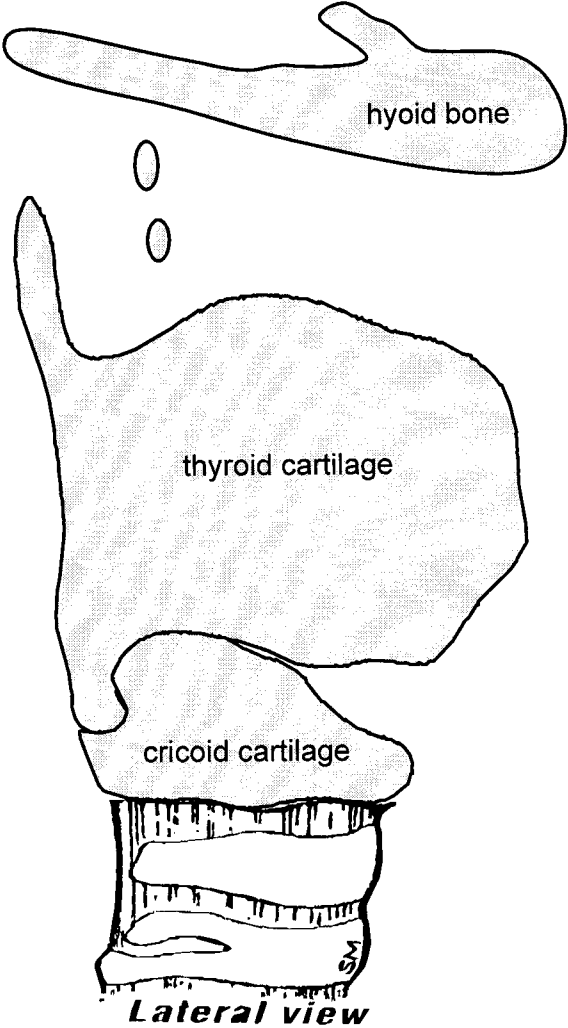
1. Anterior belly of digastric muscle
2. Posterior belly of digastric muscle
3. Mylohyoid muscle
4. Thyrohyoid membrane
5. Thyrohyoid muscle
6. Cricothyroid membrane
7. Cricothyroid muscle
8. Sternothyroid muscle
9. Sternohyoid muscle
10. Superior belly omohyoid
11. Posterior belly omohyoid
12. Thyroid gland
13. Laryngeal prominence
14. Vagus nerve
15. Recurrent laryngeal nerve
16. Superior laryngeal nerve
17. Internal laryngeal nerve
18. External laryngeal nerve
19. Lingual nerve
20. Hypoglossal nerve
21. Nerve to mylohyoid
22. Facial nerve (digastric br.)
23. Superior thyroid artery
24. Inferior thyroid artery
25. Superior laryngeal artery



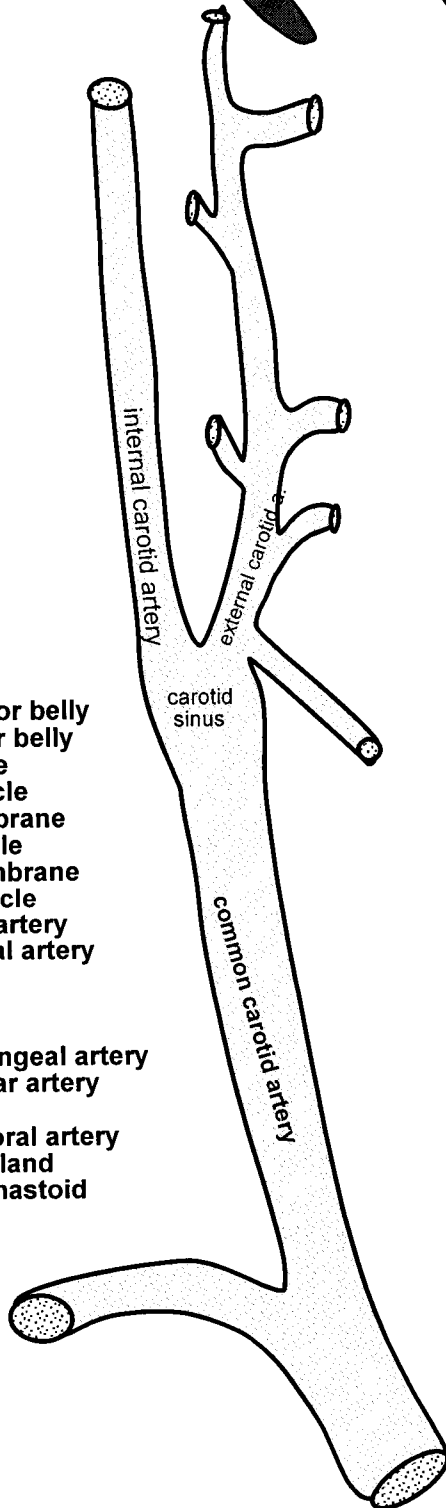
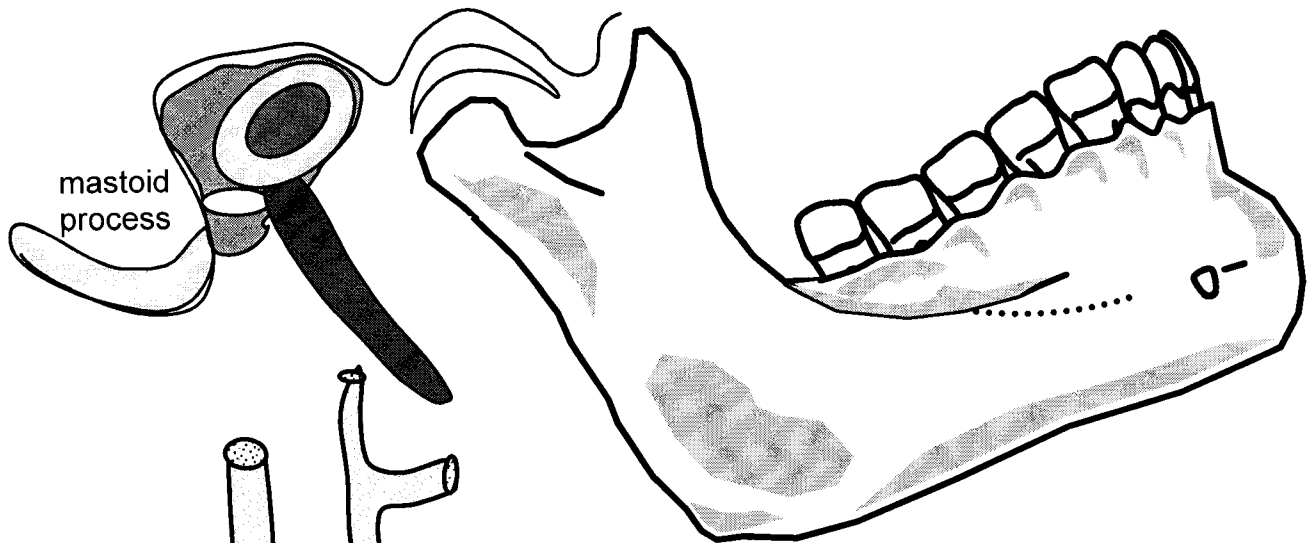
Anterior Triangle (Lateral View) - Nerves



1. Digastric, posterior belly
2. Digastric, anterior belly
3. Mylohyoid muscle
4. Hyoglossus muscle
5. Thyrohyoid membrane
6. Thyrohyoid muscle
7. Cricothyroid membrane
8. Cricothyroid muscle
9. Auriculotemporal nerve
10. Facial nerve
11. Nerve to mylohyoid
12. Lingual nerve
13. Hypoglossal nerve
14. Nerve to thyrohyoid
15. Superior root ansa cervicalis
16. Inferior root ansa cervicalis
17. Vagus nerve
18. Superior laryngeal nerve
19. Internal laryngeal nerve
20. External laryngeal nerve
21. Recurrent laryngeal nerve



Anterior Triangle (Lateral View) - Arteries



1. Digastric, posterior belly
2. Digastric, anterior belly
3. Mylohyoid muscle
4. Hyoglossus muscle
5. Thyrohyoid membrane
6. Thyrohyoid muscle
7. Cricothyroid membrane
8. Cricothyroid muscle
9. Superior thyroid artery
10. Superior laryngeal artery
11. Lingual artery
12. Facial artery
13. Occipital artery
14. Ascending pharyngeal artery
15. Posterior auricular artery
16. Maxillary artery
17. Superficial temporal artery
18. Submandibular gland
19. Artery to Sternomastoid

