

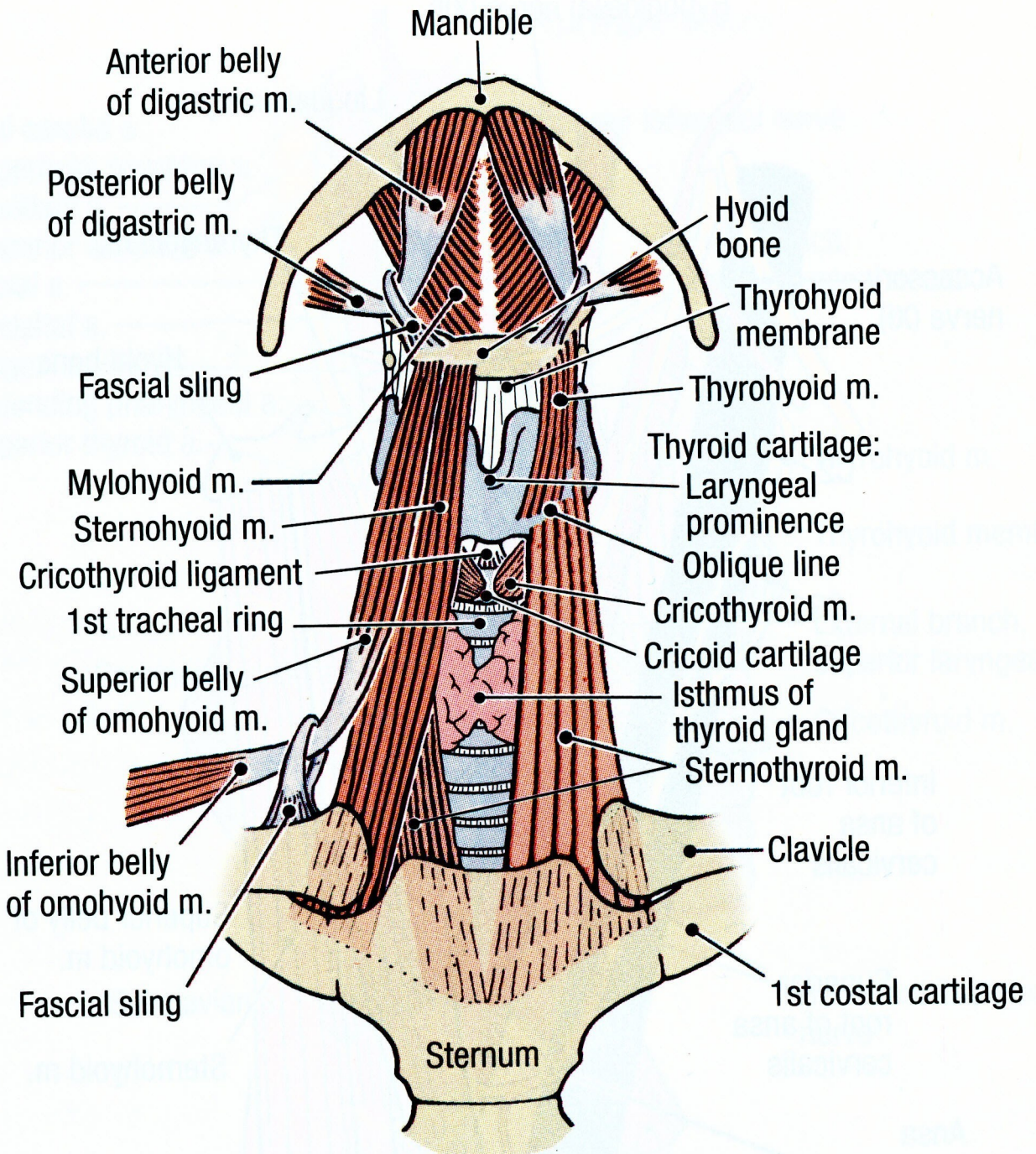Figure 7.45. The muscular triangle of the neck.

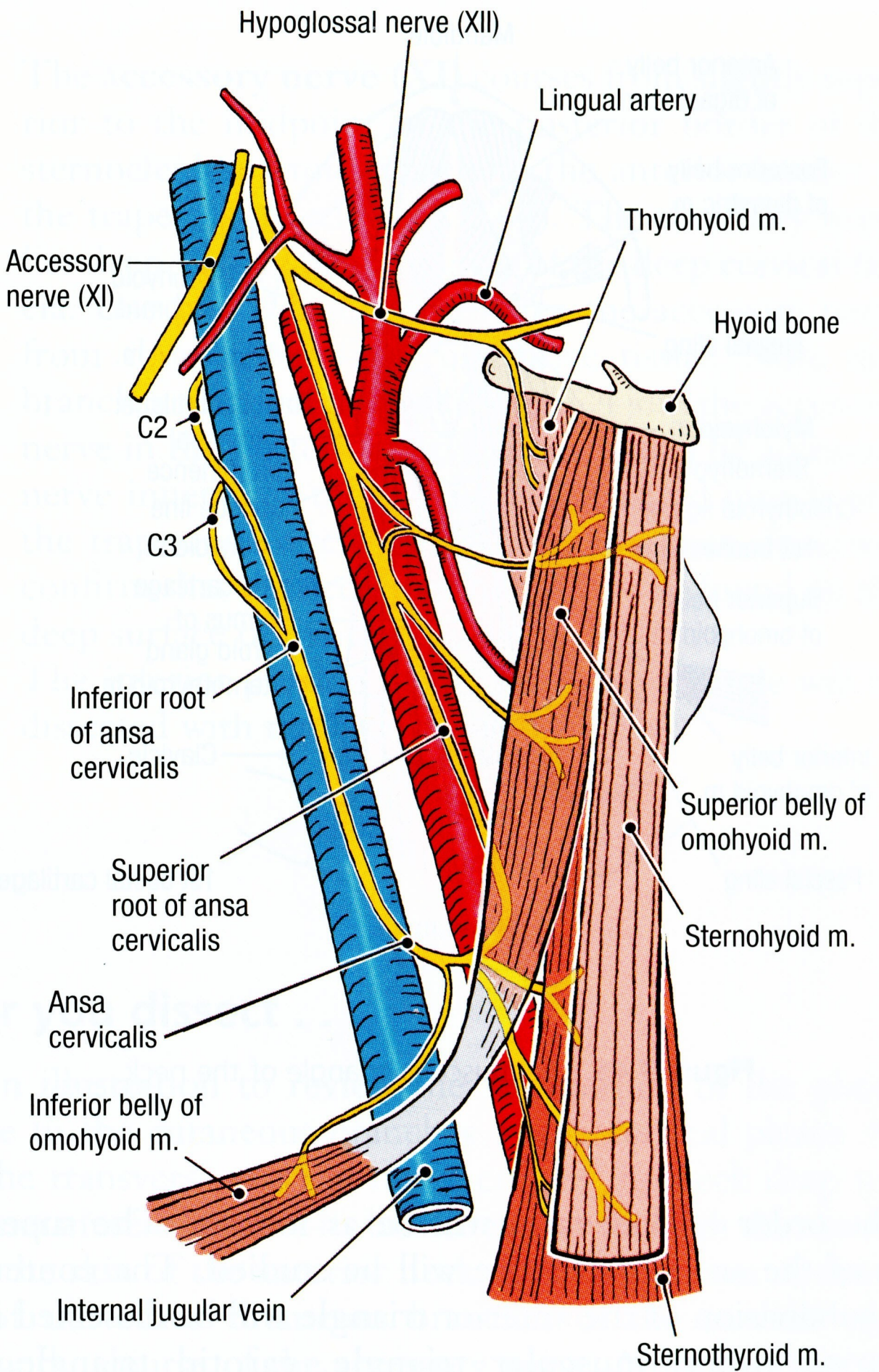


Figure 7.47. The ansa cervicalis.

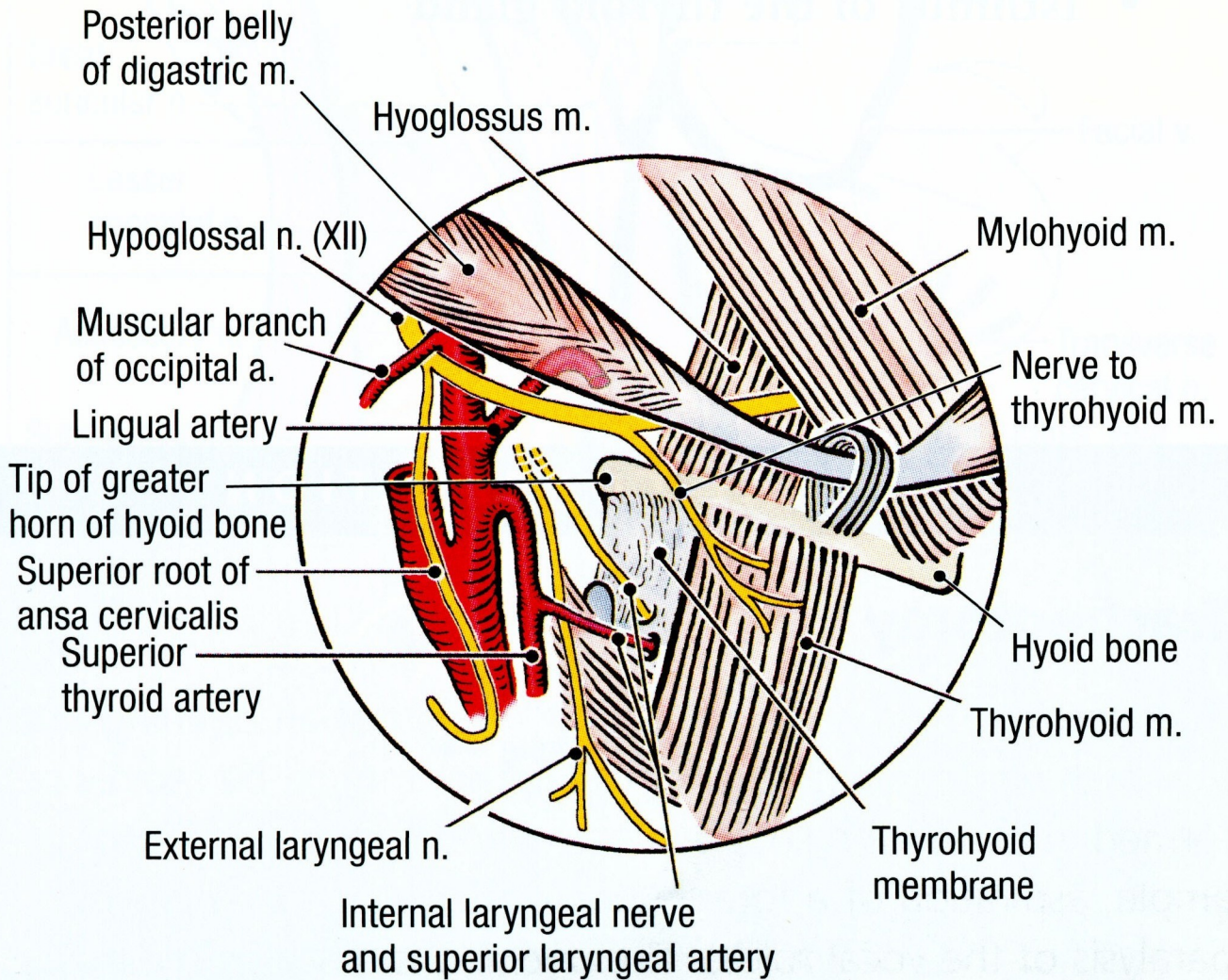


Figure 7.46. The carotid triangle of the neck. The tip of the greater horn of the hyoid bone is an important reference point.

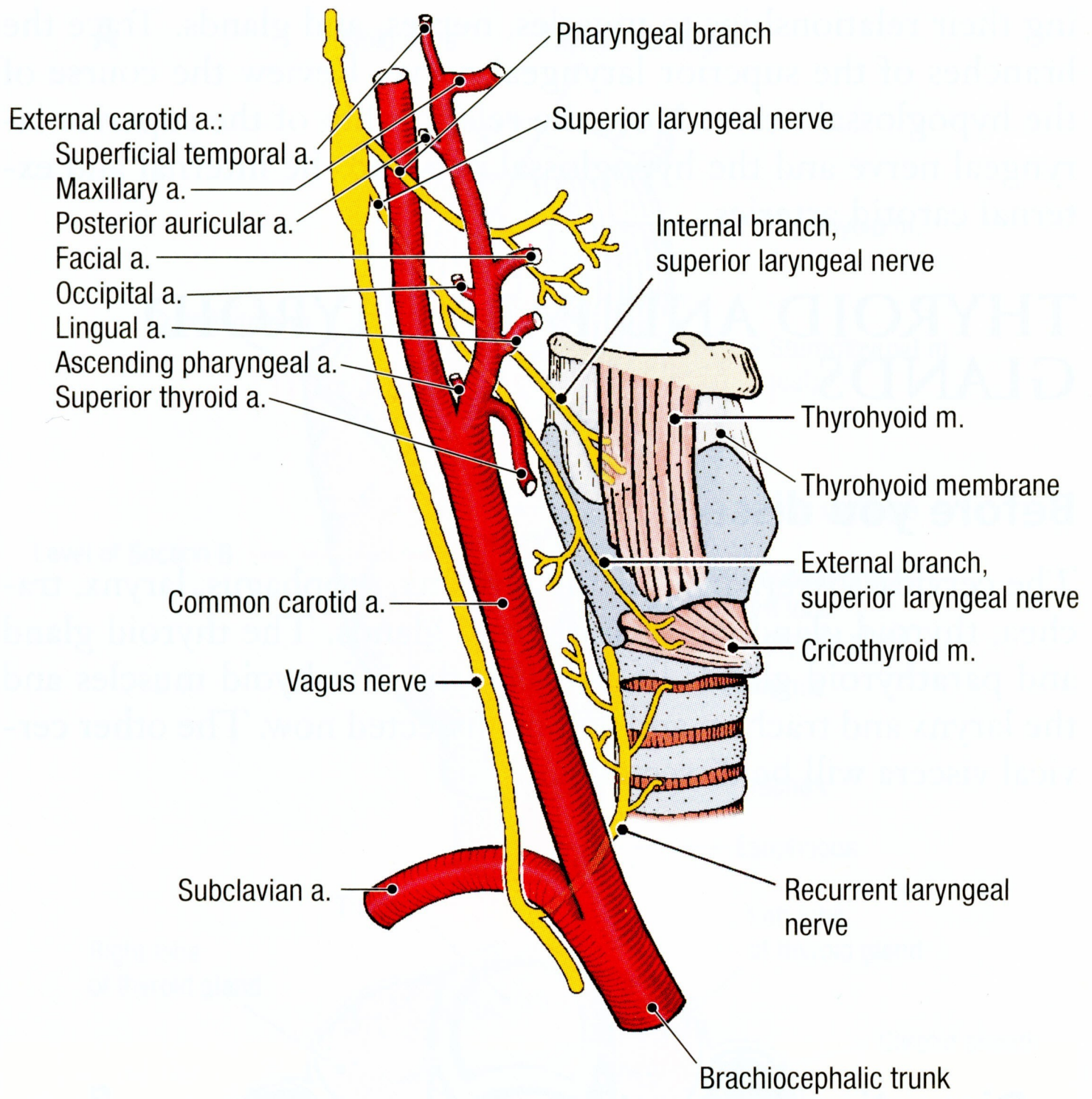


Figure 7.48. Branches of the external carotid artery and right vagus nerve (X) in the neck.

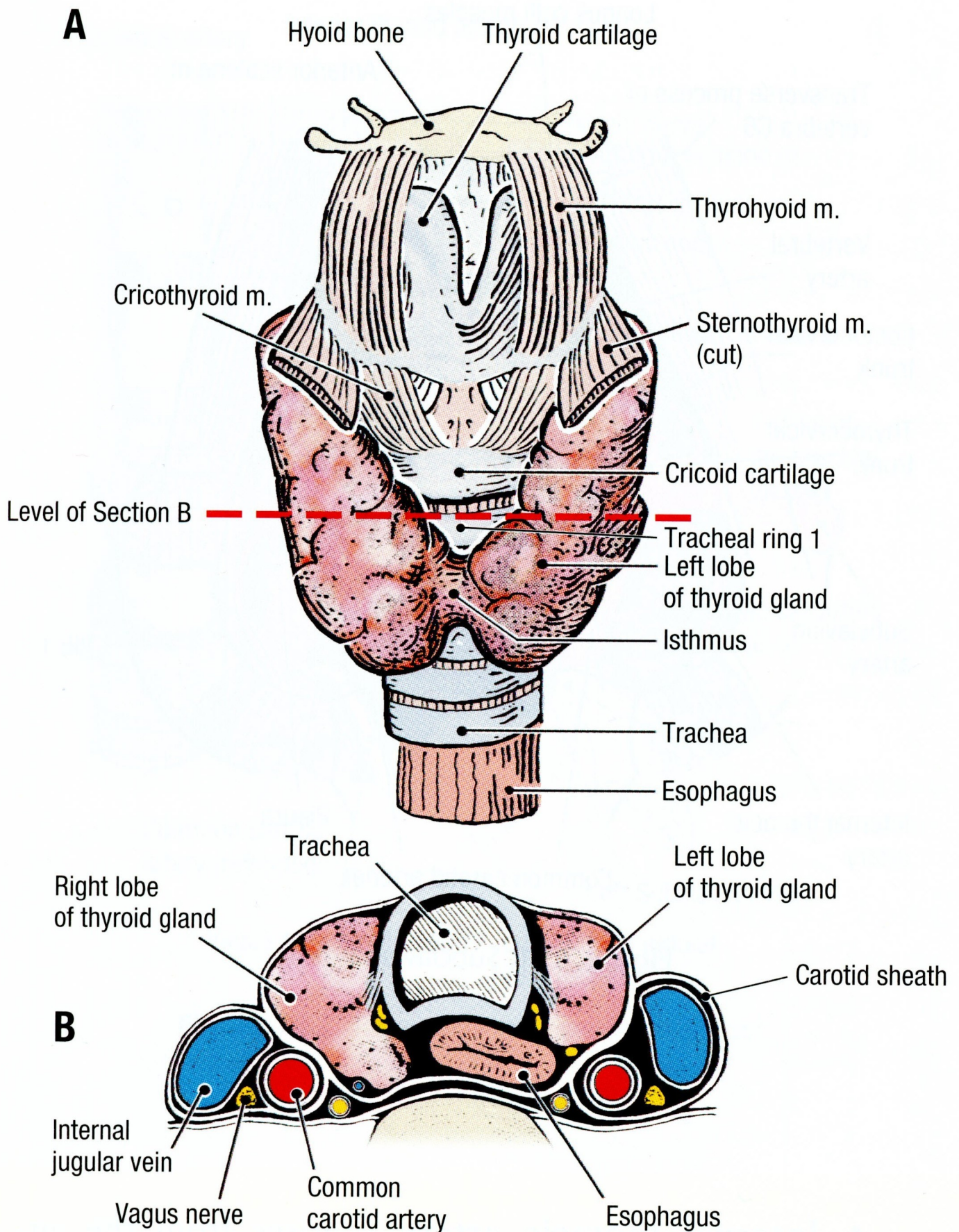


Figure 7.49. The relationships of the thyroid gland. **A.** Anterior view. Dashed line indicates the level of section. **B.** Transverse section.

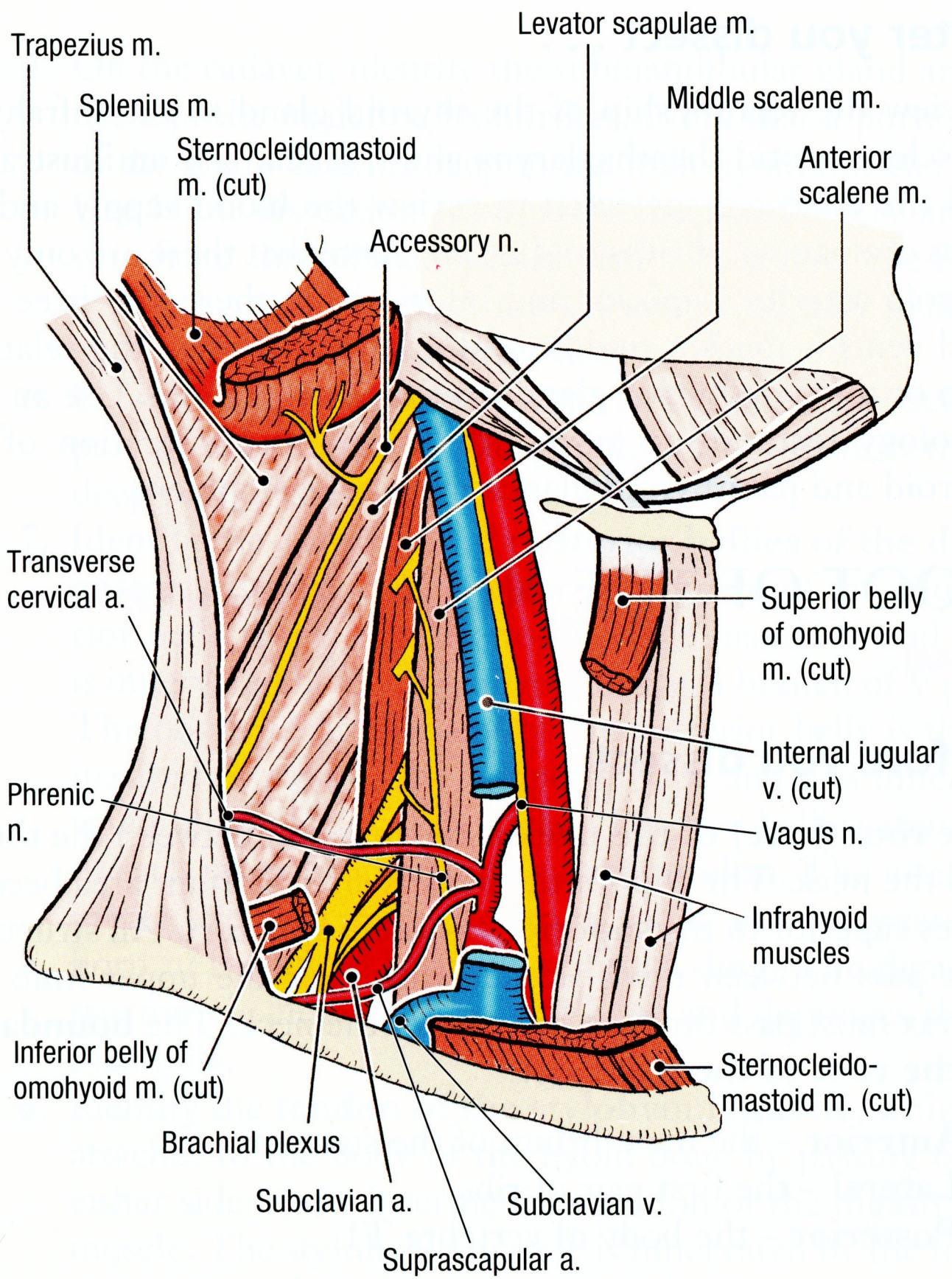


Figure 7.50. The root of the neck.

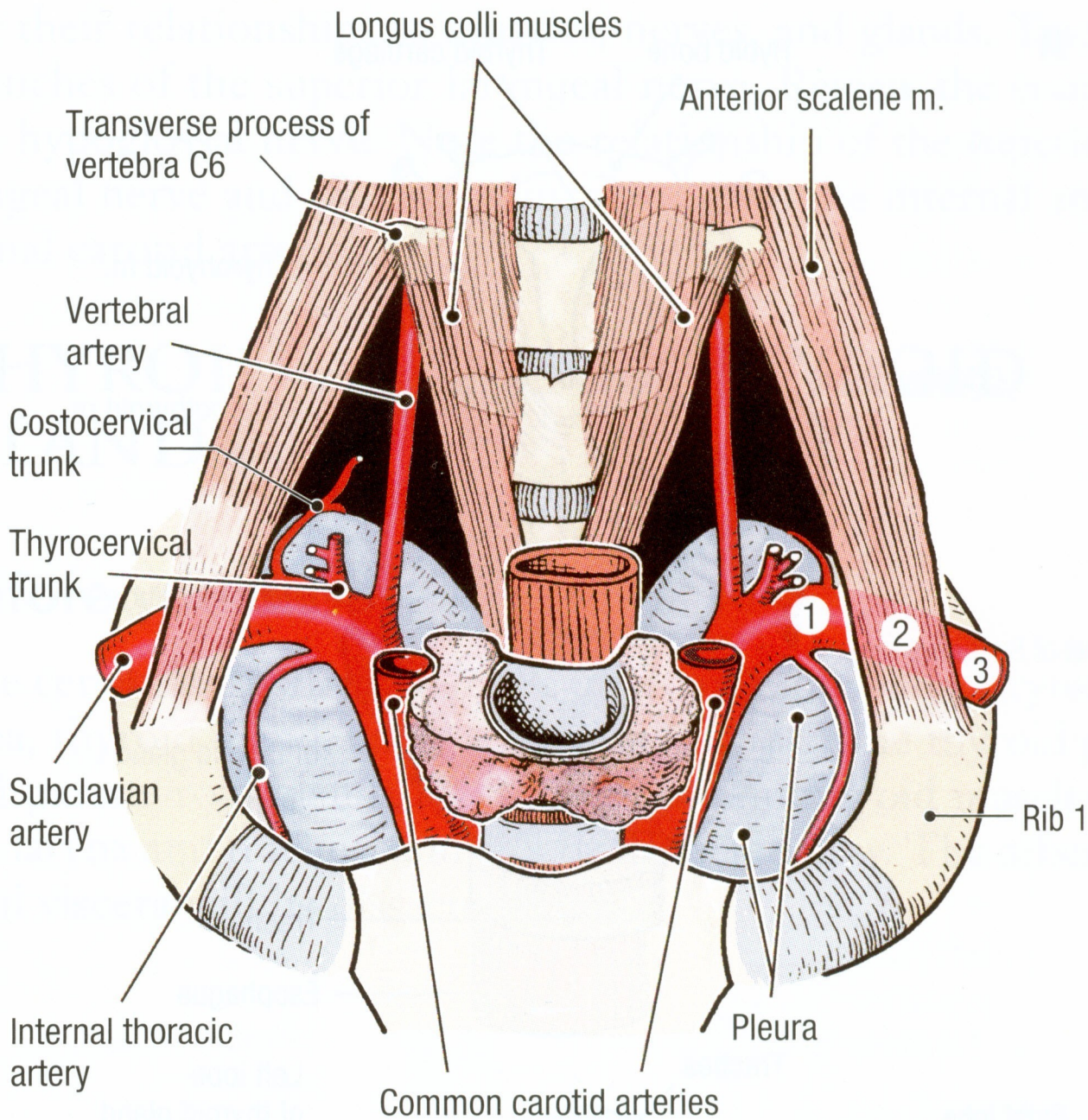


Figure 7.51. Subclavian artery.

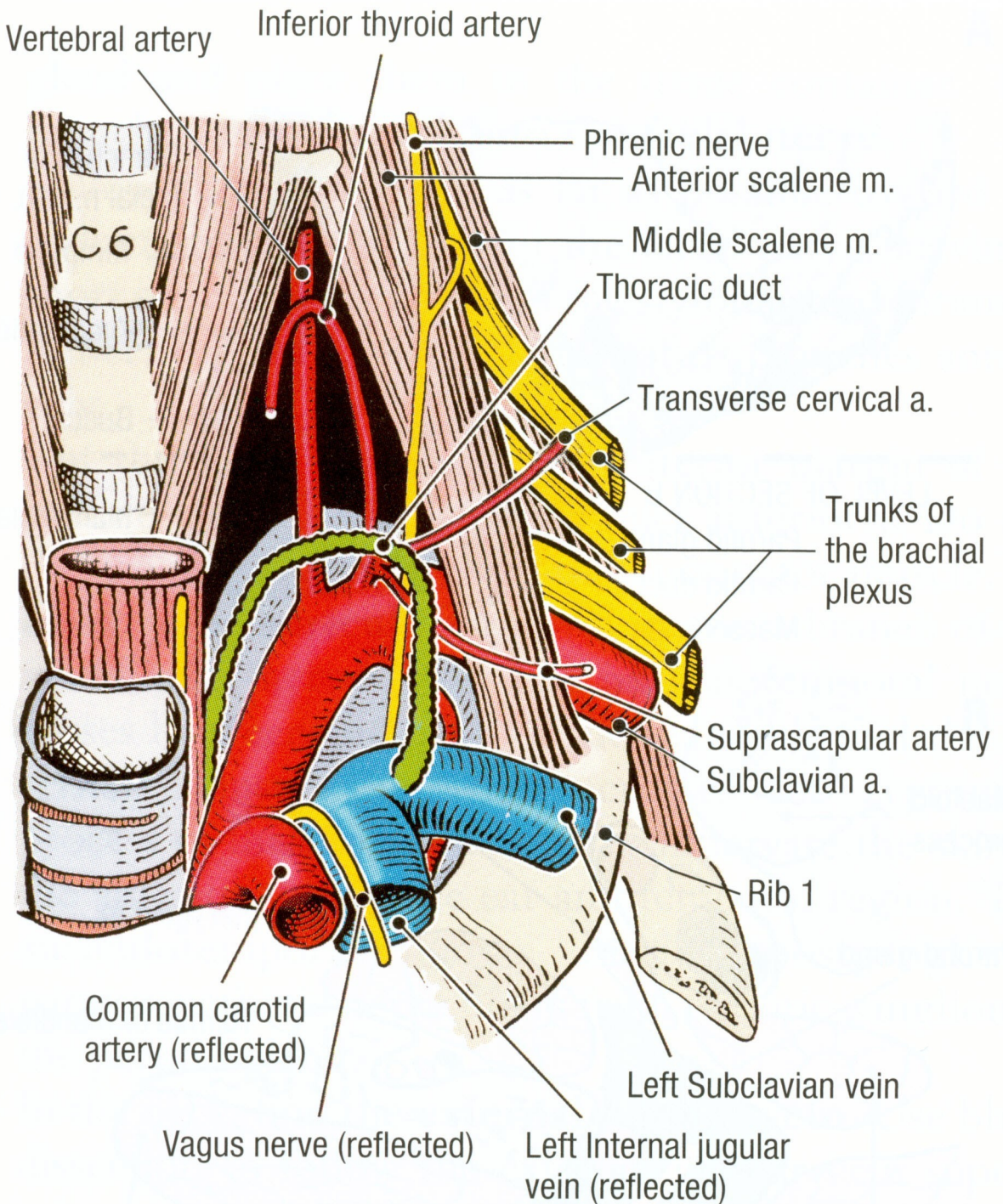


Figure 7.52. Termination of the thoracic duct.