

External Occipital Protuberance

Mastoid Process

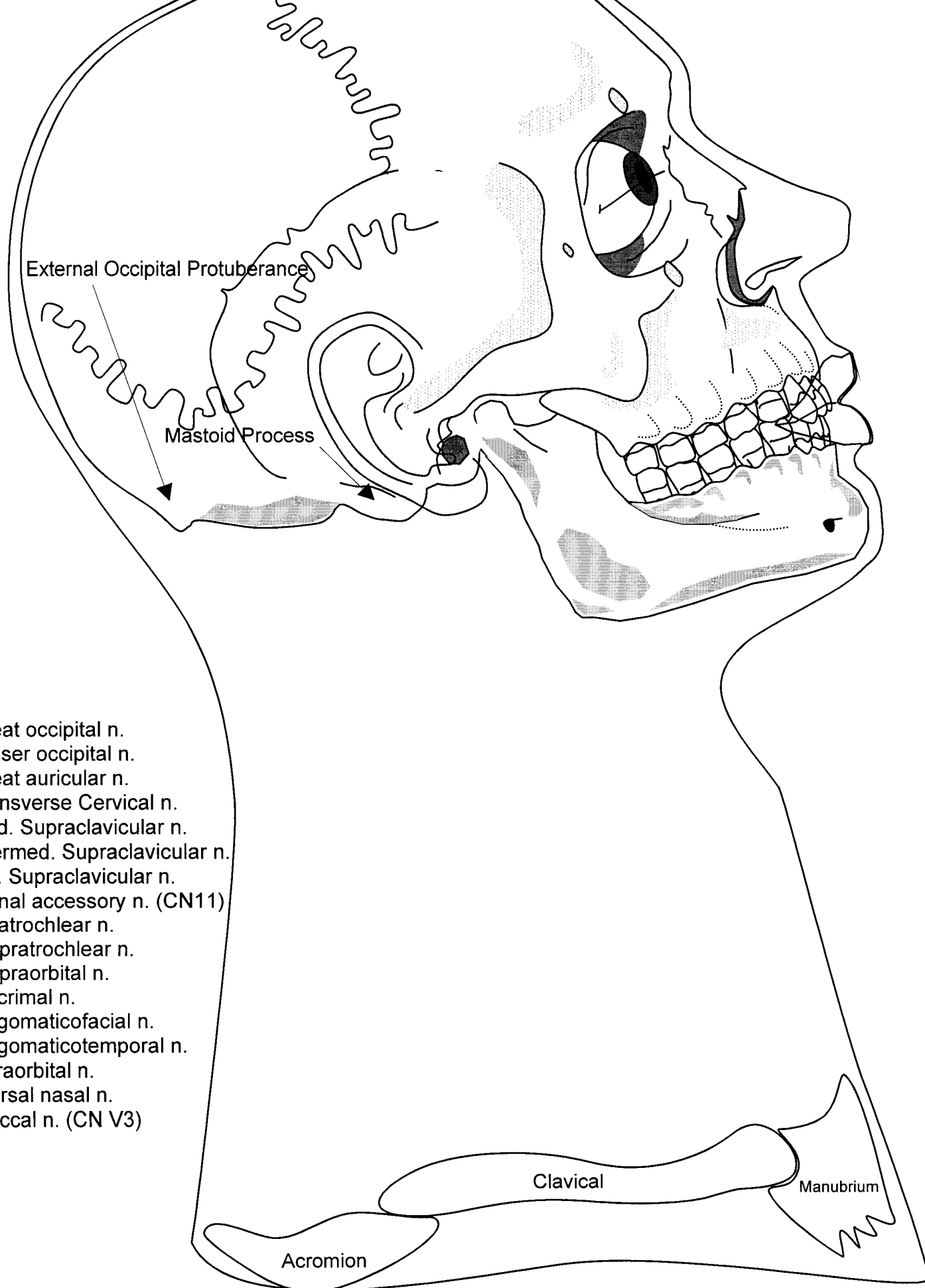
1. Superficial temporal v.
2. Retromandibular v.
3. Maxillary v.
4. External Jugular v.
5. Subclavian v.
6. Supratrochlear v.
7. Supraorbital v.
8. Angular v.
9. Infraorbital v.
10. Facial v.
11. Common facial v.
12. Internal Jugular v.
13. Anterior jugular v.
14. Occipital v.
15. Posterior auricular v.
16. Transverse cervical v.
17. Suprascapular v.
18. Cavernous Sinus
19. Ophthalmic v.
20. Parietal emissary v.
21. Pterygoid venus plexus

Clavical

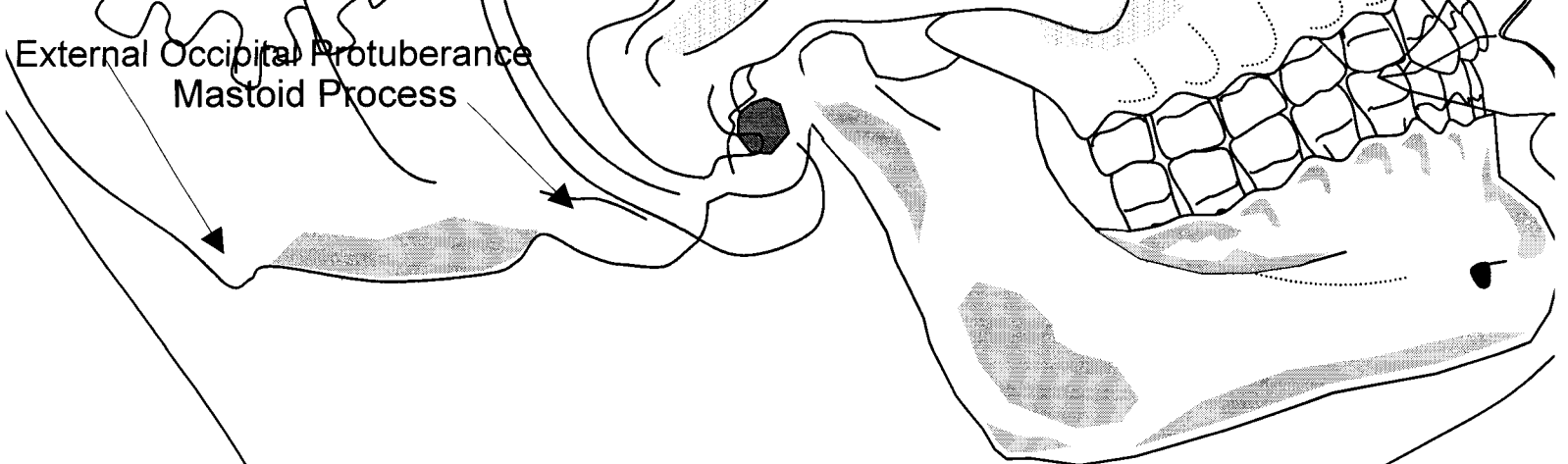
Manubrium

Acromion

Posterior Triangle - Boundaries and Superficial Venous Drainage

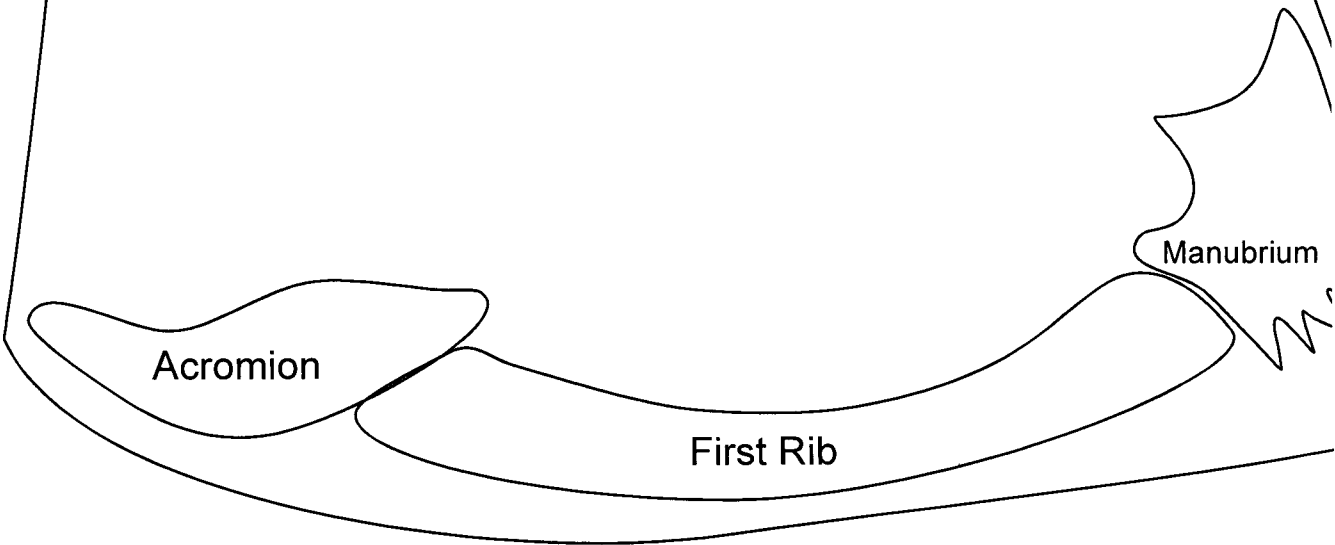


Posterior Triangle - Cutaneous Nerves and Facial Artery



External Occipital Protuberance
Mastoid Process

1. Levator Scapular M.
2. Scalenus Posterior
3. Scalenus Medius
4. Scalenus Anterior
5. Subclavius
6. Spinal Accessory N.
7. Ventral Ramus C5
8. Ventral Ramus C6
9. Ventral Ramus C7
10. Ventral Ramus C8
11. Spinal Accessory N.
12. Dorsal Scapular N.
13. Long Thoracic N.
14. Suprascapular N.
15. Phrenic N.
16. Subclavian A.
17. Thyrocervical Trunk
18. Transverse Cervical A.
19. Dorsal Scapula A.
20. Suprascapular A.

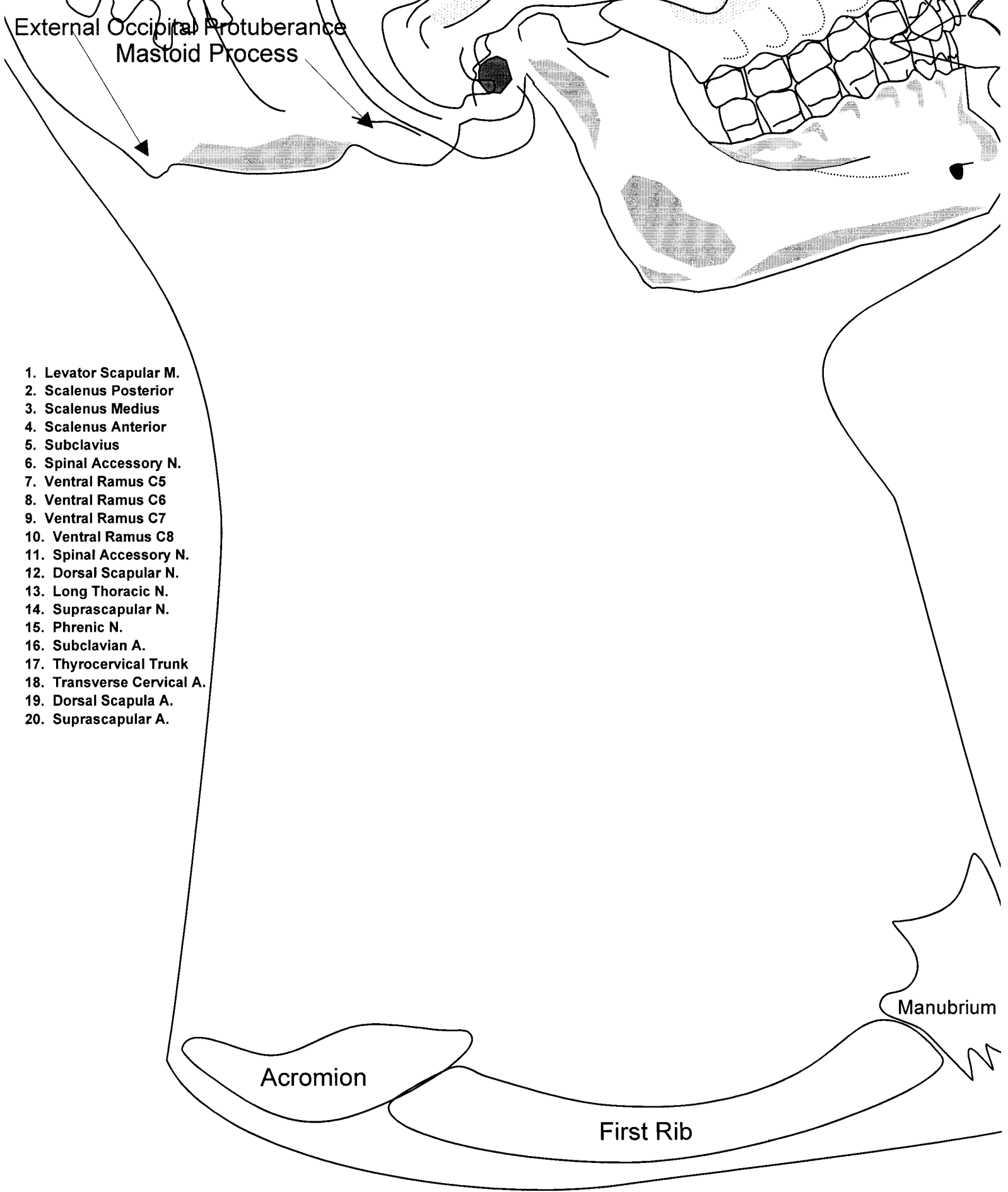


Acromion

First Rib

Manubrium

Posterior Triangle - Deep Nerves



Posterior Triangle - Deep Arteries