

STRUCTURAL BASIS OF MEDICAL PRACTICE
EXAMINATION 3

September 21, 2006

PART I. Answer in the space provided. (8 pts)

1. Identify the region. (0.5 pt)

a. Right Hypochondriac

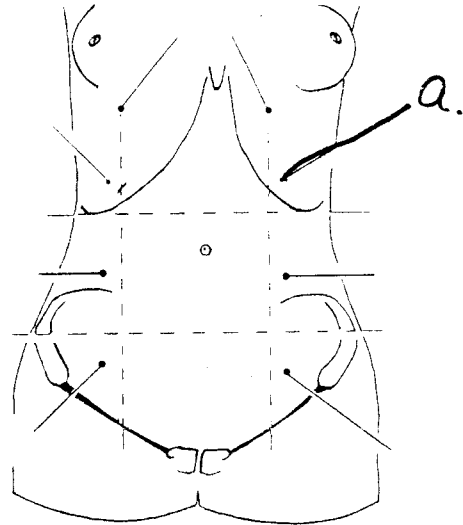


Figure 4.03. The nine abdominal regions.

2. Identify the structures. (1 pt)

a. Diaphragm
b. Lateral femoral cutaneous nerve

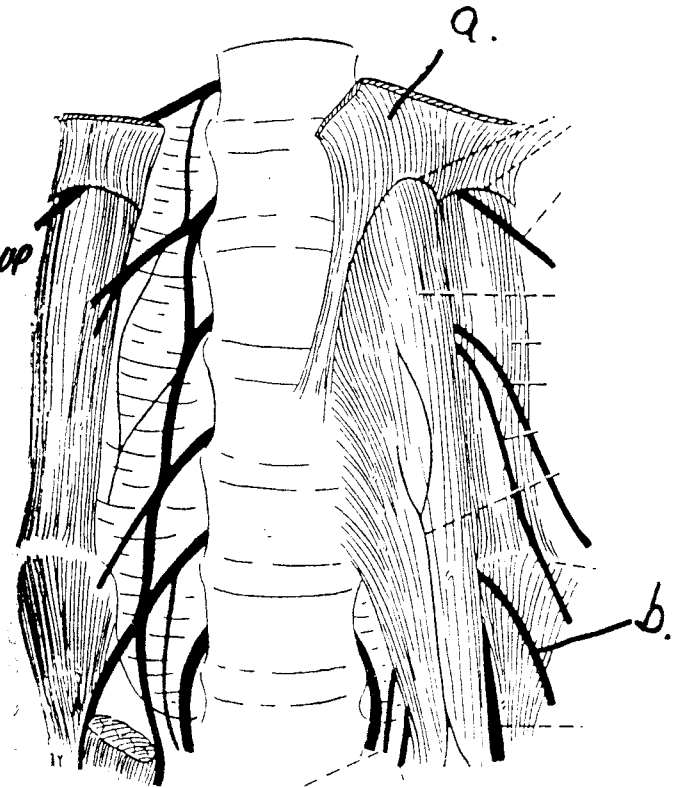


FIGURE 25-2.
The lumbar plexus

3. Identify the structures. (1 pt)

- a. UDs (ductus) deferens
- b. Pampiniform plexus of veins

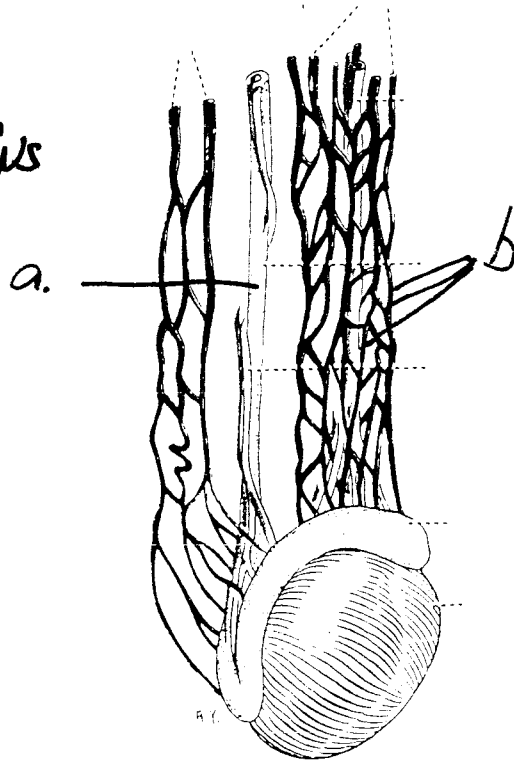
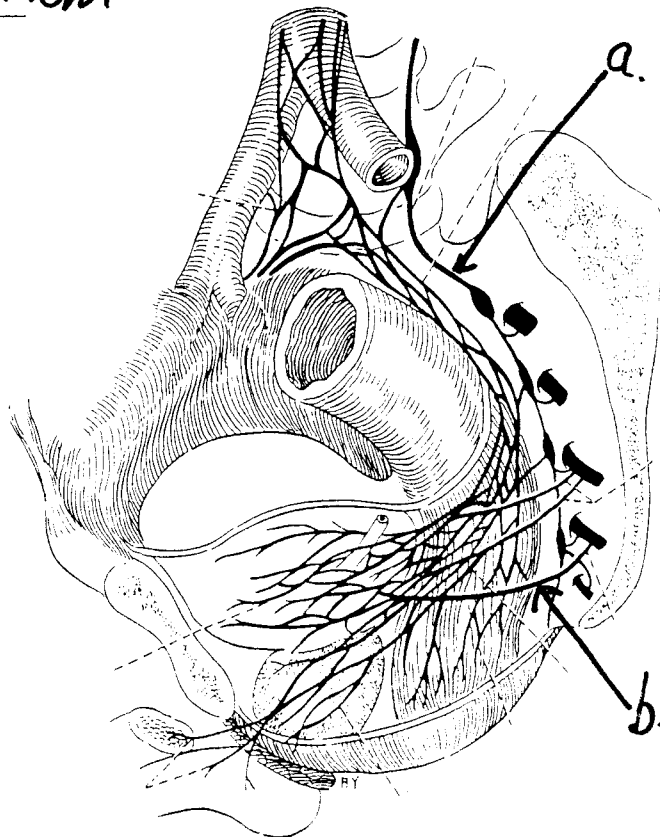


FIGURE 26-6.
Blood supply of the testis.

4. Identify the structure. (1 pt)

- a. Sympathetic Trunk
- b. Pelvic Splanchnic Nerve



5. Identify the structures. (1 pt)

- a. Common Bile Duct
- b. Superior Mesenteric Artery

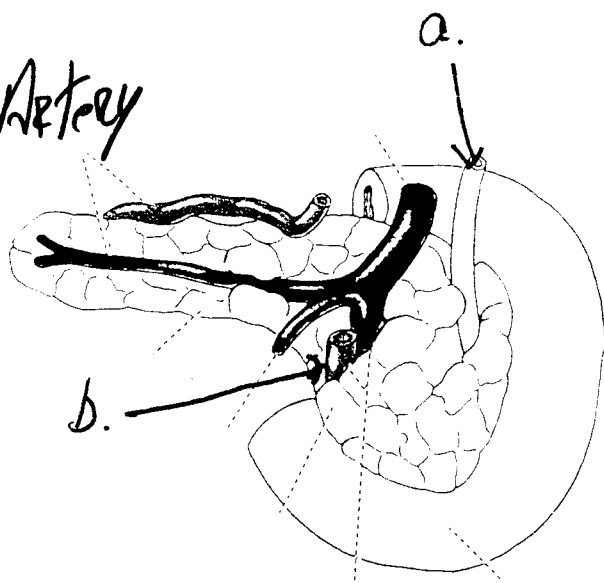


FIGURE 24-19.
Posterior view of the pancreas.

6. Identify the structures. (1 pt)

- a. Dorsal/Arcuate of Penis
- b. Deep Artery of Penis

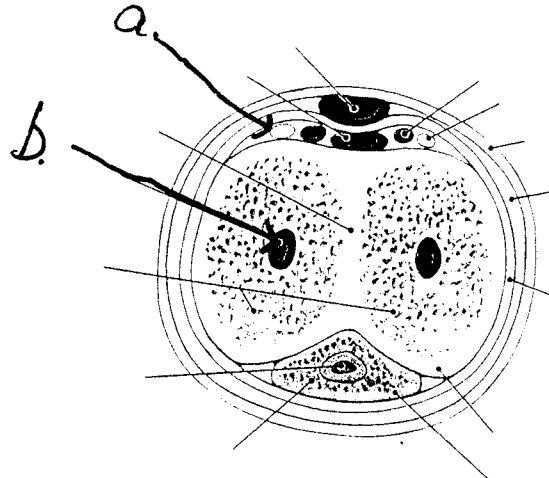


Figure 5.09. Transverse section through the body of the penis.

7. Identify the structure. (1 pt)

- a. Anococcygeal raphe
- b. Nervus terminalis

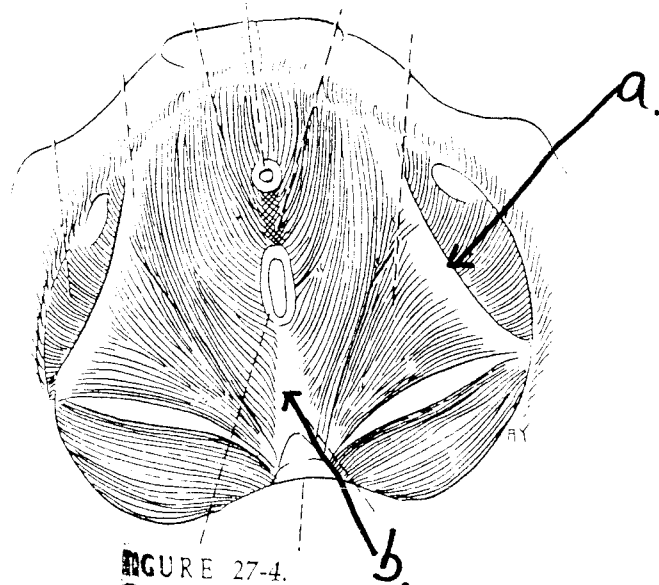


FIGURE 27-4.
The levator ani from above.

8. Identify the structure. (1.5 pts)

- a. Perineal body (Central tendon)
- b. Inferior Rectal Vessels
- c. Deep Artery of Clitoris

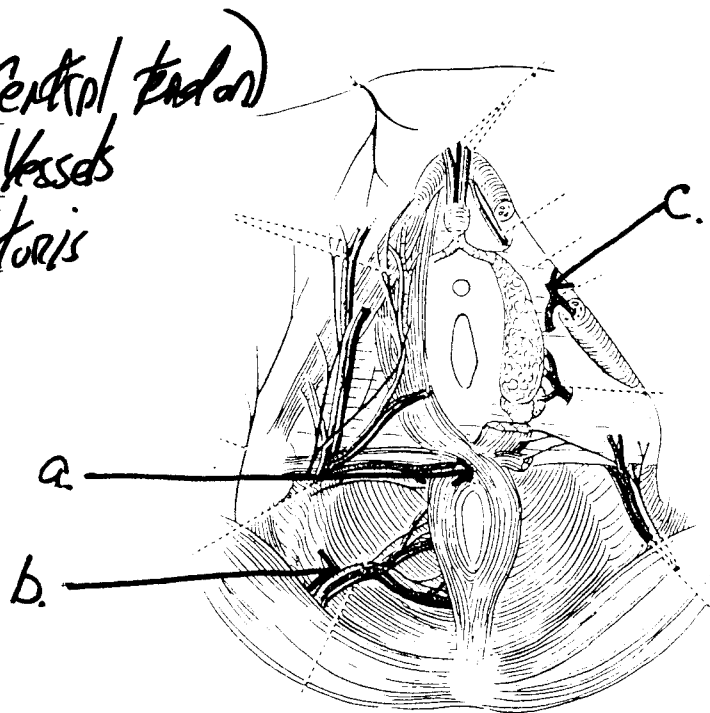


FIGURE 28-23.
Nerves and vessels of the female perineum.

Part II. Circle the correct answer. All, none, or some may apply. (26 pts)

1. With respect to the abdominal wall:

- a. a. Nerves and vasculature of the anterior abdominal wall travel in the neurovascular plane, located between the external oblique and transversus abdominis muscles.
- b. The paraumbilical veins in the anterior abdominal wall drain, in part, to the superficial epigastric vein.
- c. Scarpa's fascia continues into the penis as Buck's fascia.
- d. The suspensory ligament is a specialization of tela subcutanea.
- e. The paraumbilical veins drain, in part, to the portal vein.
- f. The internal oblique muscle arises, in part, from the lateral two-thirds of the inguinal ligament.
- g. The umbilicus and the iliac crest are at the level of approximately L4.
- h. The pectineal ligament is derived from the inguinal and lacunar ligaments.

2. With respect to the abdominal vasculature:

- a. The portal vein is formed posterior to the neck of the pancreas.
- b. The inferior vena cava is formed by the junction of the two common iliac veins at about the level of L5.
- c. The ovarian arteries are branches of the anterior division of the internal iliac artery.
- d. The middle suprarenal arteries arise from the aorta at or superior to the origin of the renal artery.
- e. The left renal vein drains into directly into the inferior vena cava.
- f. The renal arteries arise just inferior to the inferior mesenteric artery.
- g. The short gastric arteries are located in the gastrosplenic ligament.
- h. The anterior, but not the posterior, superior pancreaticoduodenal artery is intraperitoneal.

3. In the nervous system associated with the abdomen and pelvis:
- a. Transection of the spinal cord only through the dorsal root at S2-4 produces an "atonic" bladder.
 - b. The ischiocavernosus muscle is skeletal muscle innervated by perineal branches of the pudendal nerve.
 - c. The corpus spongiosum is innervated by somatic nerves associated with the pudendal nerve.
 - d. Helicine arteries are stimulated to vasodilate by the parasympathetic nervous system.
 - e. Parasympathetic (autonomic) nerves, derived from the pelvic splanchnic nerves, stimulate peristalsis in the sigmoid colon.
 - f. Sympathetic innervation of the duodenum is by way of the lumbar splanchnic nerves.
 - g. The sacral sympathetic trunk has white rami communicans.
 - h. The posterior scrotal/labial nerves are derived from the pudendal nerve.
4. With regard to the thoracic diaphragm
- a. The esophageal hiatus is formed by the left crus.
 - b. The thoracic duct ascends through the aortic hiatus.
 - c. The median arcuate ligament is derived from the right and left crus.
 - d. The vagal trunks pass from the thorax to the abdomen through the esophageal hiatus.
 - e. The foramen for the inferior vena cava lies at approximately the level of T10.
 - f. The sympathetic trunks descend deep (posterior) to the medial arcuate ligaments.
 - g. The azygous and hemiazygous veins pass through the aortic hiatus.
 - h. The lumbocostal trigone is a potential area of weakness just superior to the lateral arcuate ligament.
5. With respect to the fascia of the abdomen, pelvis, and perineum:
- a. The superior, but not the inferior, fascia of the urogenital diaphragm is considered parietal pelvic fascia.

- b. The arcus tendineus is a specialization of the obturator internus fascia.
 - c. The inferior surface of the thoracic diaphragm is associated with transversalis fascia.
 - d. The periprostatic fascia is a specialization of the parietal pelvic fascia.
 - e. The visceral pelvic fascia forms the renal fascia.
 - f. The Cardinal ligaments are specializations of the visceral pelvic fascia.
 - g. The pudendal canal is formed by parietal pelvic fascia.
 - h. The perirenal fat is derived from extraperitoneal connective tissue.
6. With regard to the abdomen, pelvis, and perineum:
- a. The sacrum is composed of 5 vertebrae.
 - b. The pelvic outlet is formed by the superior aspect of the pubic symphysis, the pelvic brim, and the sacral promontory.
 - c. In females, the greater (false) pelvis is shallower than in males.
 - d. The trigone of the bladder is formed by detrusor muscle.
 - e. The artery of the ductus (vas) deferens is derived from the inferior epigastric artery.
 - f. Venous drainage superior to the pectinate line is to the inferior rectal veins.
 - g. The prostatic sinus is located on the seminal colliculus.
 - h. The "puborectal sling" refers to the pubococcygeus muscle.
 - i. The caudate lobe and the left half of the quadrate lobe of the liver are part of the structural vascular distribution of blood vessels of the left lobe.
 - j. The umbilical arteries carry oxygenated blood to the fetus.
 - k. The superior mesenteric vessels arise superior to the 3rd part of the duodenum.
 - l. The duodenal cap does not contain plicae circulares.