

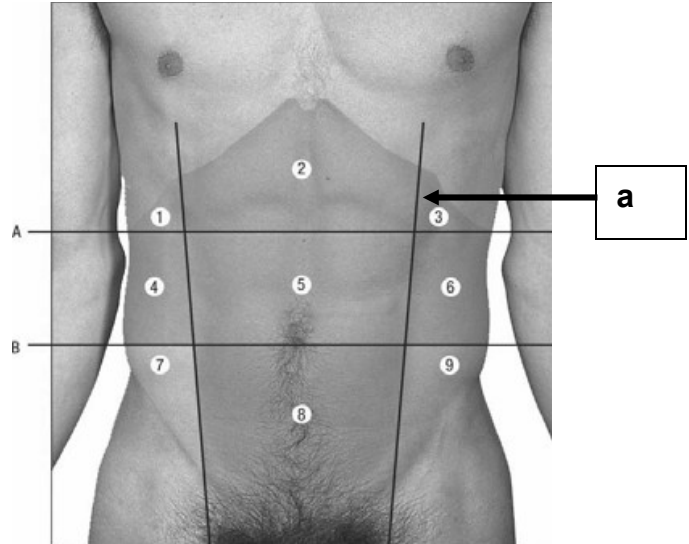
**STRUCTURAL BASIS OF MEDICAL PRACTICE
EXAMINATION 3**

September 15, 2011

PART I. Answer in the space provided. (7 pts)

1. Identify the region. (0.5 pt)

a. _____

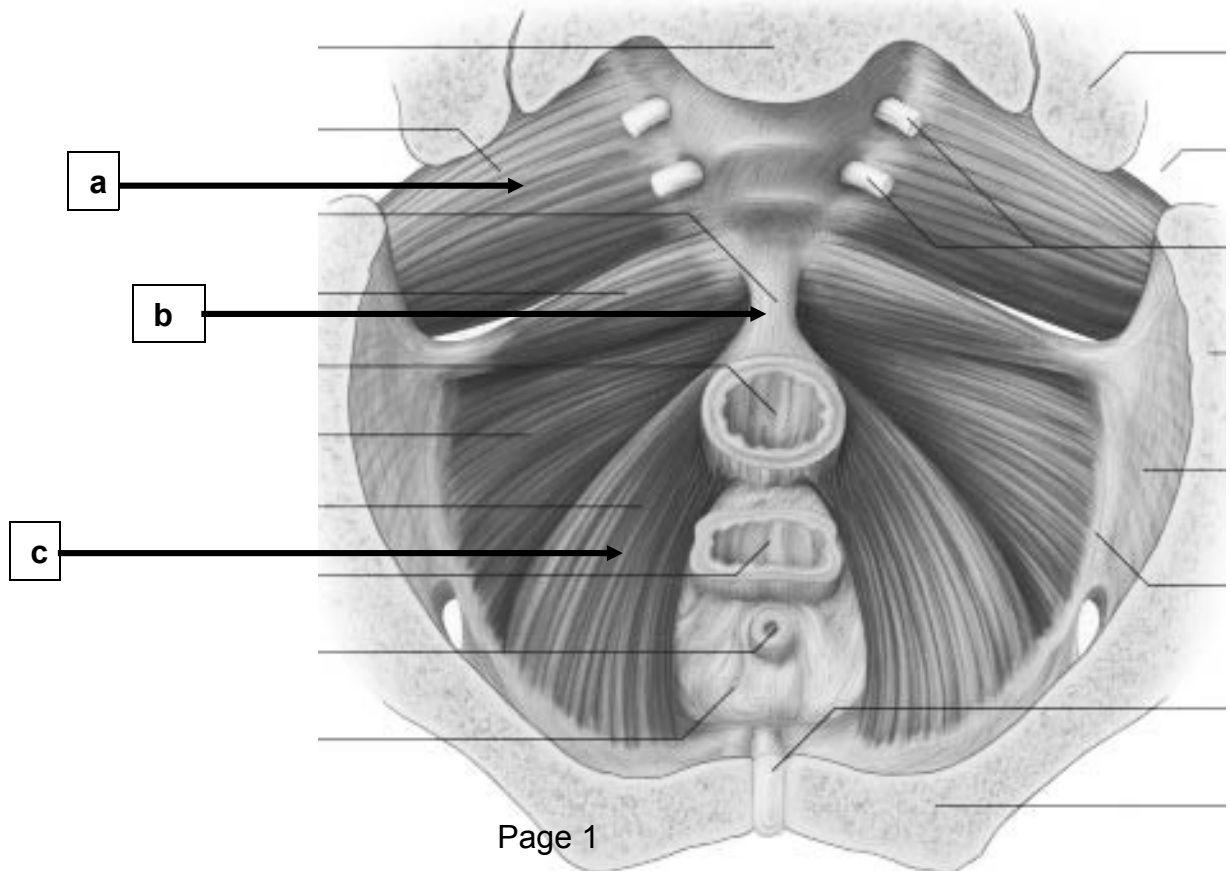


2. Identify the structure. (1.5 pt)

a. _____

b. _____

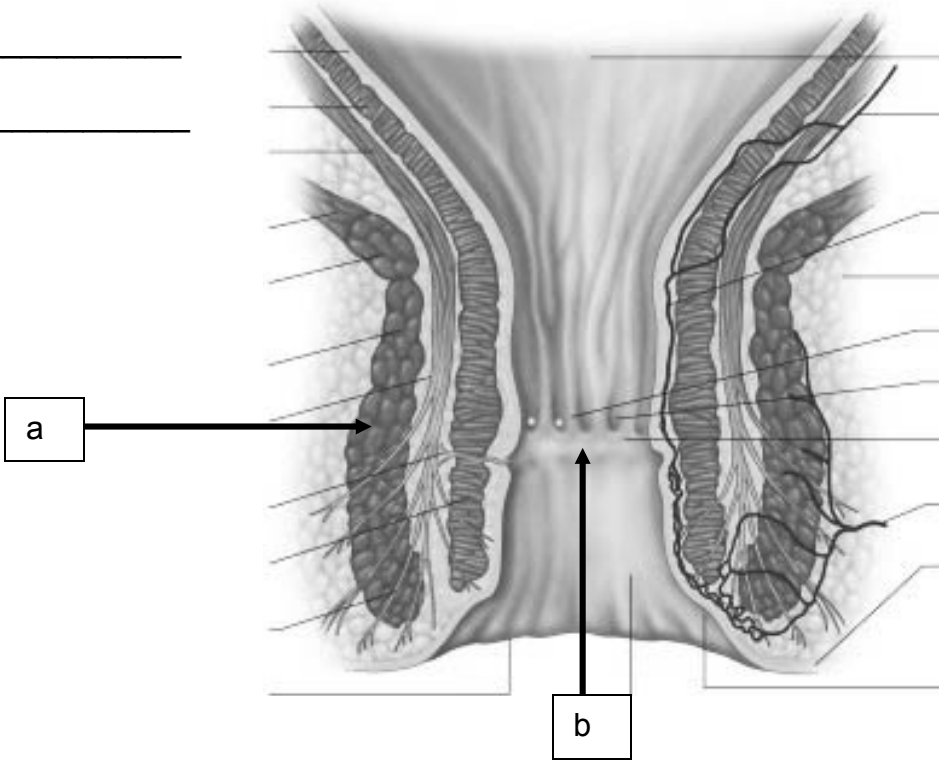
c. _____



3. Identify the structures. (1 pt)

a. _____

b. _____



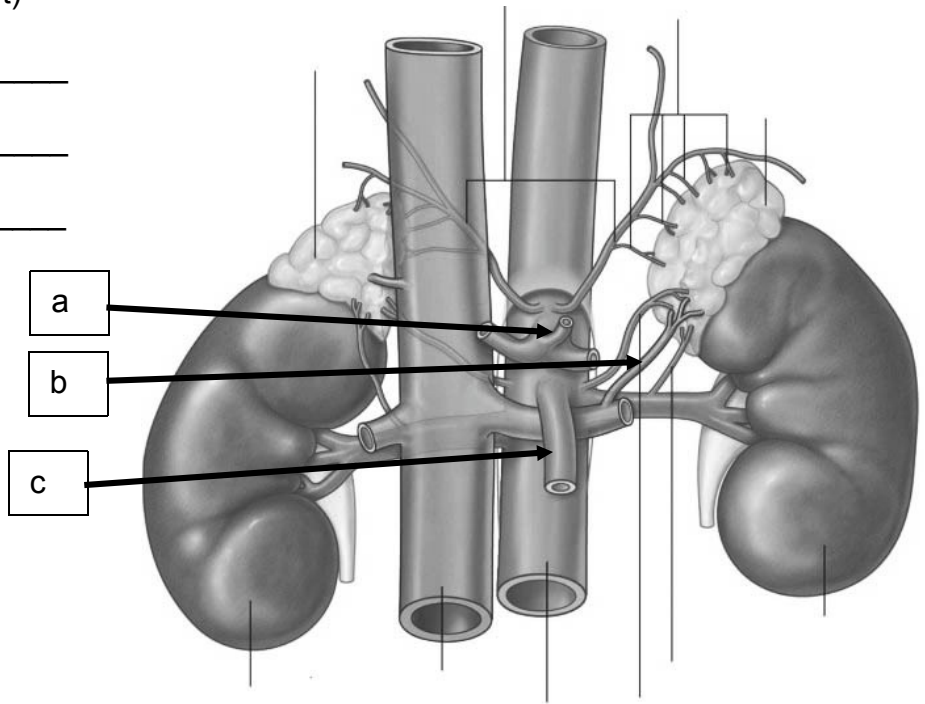
4.

Identify the structures. (1.5 pt)

a. _____

b. _____

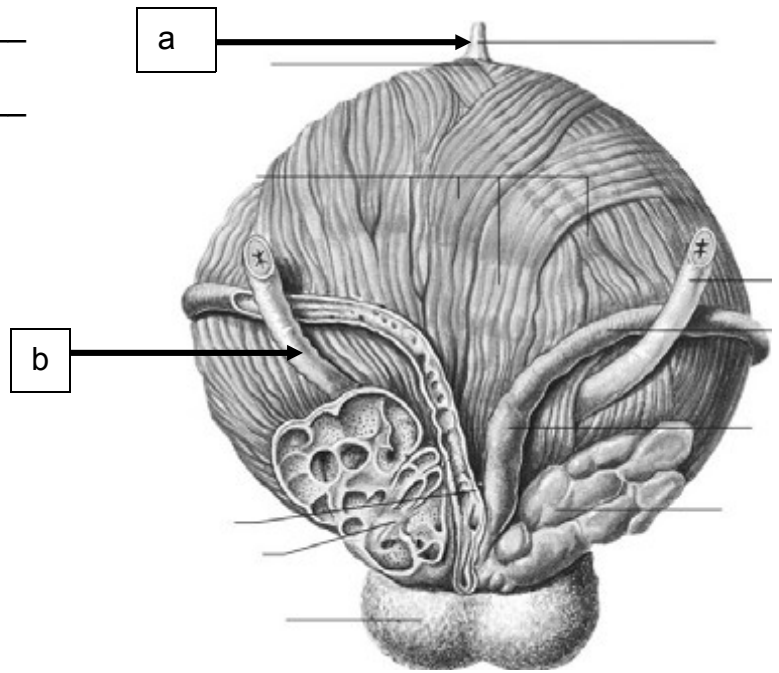
c. _____



5. Identify the structures. (1 pt)

a. _____

b. _____

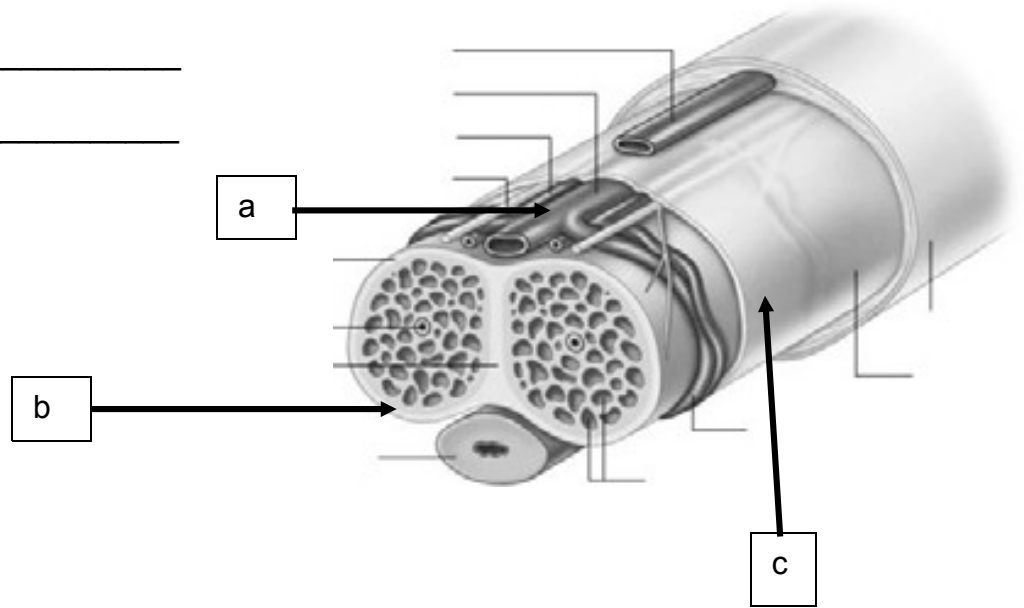


6. Identify the structures. (1.5 pt)

a. _____

b. _____

c. _____



c. _____

Part II. Circle the correct answer. All, none, or some may apply. (27 pts)

a. 1. In regard to the abdominal and pelvic nerves and vessels:

- a. Transection of the spinal cord at the level of S2-4 is termed an automatic bladder.
- b. The pelvic splanchnic nerves are termed the "nervi erigentes" and vasodilate the helicine veins.
- c. The hypogastric nerves lie in uncondensed transversalis fascia.
- d. The cavernous nerves are derived from the pudendal nerve.
- e. The celiac ganglia are located at the level of L1.
- f. The parasympathetic nerves to the testes are derived from the vagus.
- g. The sympathetic trunk can be found medial to the psoas muscle in the pelvic cavity.
- h. The deep dorsal vein of the clitoris drains into the superficial dorsal vein.
- i. The anterior labial nerves are derived from the ilioinguinal nerve.
- j. Blood in the corpora cavernosa drains by way the deep dorsal vein of the penis.
- k. Peristalsis of the hindgut is driven by parasympathetic nerves derived from S2-4.
- l. Both the external anal sphincter and the puborectalis muscle receive innervation by the somatic nervous system.

2. With respect to the abdominal vasculature:

- a. The right gastric artery courses through both the hepatoduodenal and hepatogastric ligaments.
- b. The vitelline arteries give rise to the celiac, superior mesenteric, and inferior mesenteric arteries.
- c. The ligamentum teres is the remnant of the right umbilical vein.
- d. The splenic artery courses, in part, through the lienorenal ligament.
- e. The celiac artery is located at the upper part of L3.
- f. The portal vein is formed by the convergence of the splenic, superior mesenteric, and renal veins.

- g. In contrast to the jejunum, the ileum has arcades of the intestinal branches of the superior mesenteric artery that are more complex, the windows in the mesentery are opaque rather than translucent, and have shorter vasa recta.
 - h. The right colic artery is retroperitoneal and is embedded in visceral pelvic fascia.
 - i. The middle suprarenal artery lies superior to the superior mesenteric artery.
 - j. The abdominal aorta bifurcates into the right and left common iliac arteries at the level of L4.
3. With respect to the abdomen:
- a. During development the stomach rotates 90 degrees in a clockwise direction, situating the left and right vagus nerves on the anterior and posterior wall, respectively.
 - b. The inferior vena cava and portal vein form the posterior boundary of the Epiploic Foramen of Winslow.
 - c. The phrenicocolic ligament forms a shelf for the spleen and is derived from the dorsal mesentery.
 - d. The distribution of vascular vessels in the liver show that quadrate lobe and left half of the caudate lobe are related to the left lobe of the liver.
 - e. The porta hepatis contains the portal vein, hepatic ducts, and common hepatic artery.
 - f. The obliterated umbilical arteries are situated in the extraperitoneal connective tissue.
 - g. The portal vein is derived from the cardinal veins.
 - h. The first part of the duodenum is most mobile and does not contain plicae circulares.
 - i. The lesser duodenal papilla is located superior to the greater duodenal papilla.
 - j. The transverse mesocolon is located anterior to the 2nd part of the duodenum.
 - k. Renal fascia is derived from the extraperitoneal connective tissue and, importantly, forms a shelf inferior to the kidney.
 - l. The kidneys are fully enveloped with peritoneum.
 - m. Renal columns are located in the medulla of the kidney and project into the minor calyces.

- n. The renal sinus contains perirenal fat.
 - o. The adult kidney is derived from the mesonephros.
 - p. The right suprarenal/central vein drains directly into the inferior vena cava.
 - q. The sympathetic trunk passes from the thorax to the abdomen deep to the lateral lumbocostal arch/arcuate ligament.
 - r. Pain from an inflamed appendix can be referred to the right lateral abdominal (iliac) fossa.
4. In regard to the pelvis and perineum:
- a. The superior fascia of the urogenital diaphragm is termed parietal pelvic fascia.
 - b. The uterosacral ligament is part of the pubosacral ligamentous complex and derived from the visceral pelvic fascia.
 - c. The uterus is supported by the Cardinal/lateral cervical ligaments.
 - d. Normally, the uterus is anteverted and anteflexed in the posterior direction.
 - e. The mesometrium is visceral pelvic fascia.
 - f. The superior vesical arteries are branches of the umbilical artery.
 - g. The ducts of the bulbourethral glands drain into the vestibule of the vagina.
 - h. The suspensory ligament of the clitoris is comprised of deep fascia.
 - i. The levator ani consists of the puborectalis, iliococcygeus, and ischiococcygeus muscles.
 - j. The true pelvis contains the pelvic viscera.
 - k. The prostatic venous plexus drains into the external iliac vein.
 - l. The crura of the penis lies in the superficial pouch.
 - m. Somatic pain may occur from hemorrhoids located below the pectinate line.
 - n. The inferior rectal vein drains into the internal pudendal vein.

Part III. Indicate your understanding of the following. Answer in the space provided. (30 pts)

1. There are over 20,000 new cases, and more than 15,000 deaths, each year from ovarian cancer. Only palliative care (relieving the pain and comforting the patient - but not a treatment for the cancer) is available after the re-appearance of these cancers following initial surgical resection. **Indicate the lymphatic drainage, innervation, and vasculature of the ovary.** (6 pts)

2. An indirect inguinal hernia descends into the scrotum and down to the level of the tunica vaginalis. **Discuss the anatomy of the tunica vaginalis, its relationship to the testis, and its embryological origin.** (6 pts)

3. There are 150,000 new cases, and 50,000 deaths, from colorectal cancer each year. **Discuss the innervation, vasculature, and lymphatic drainage of the descending colon.** (6 points)

4. An esophageal hiatal hernia is a defect in the diaphragm that allows the cardia and fundus of the stomach to slide upward through an enlarged esophageal hiatus. **Describe the anatomy of the esophageal hiatus and list the structures passing through this hiatus.** (6 points)

5. An enlarged prostate (benign prostatic hyperplasia - BPH) narrows the prostatic urethra. One treatment for this condition is transurethral resection of the prostate (TURP). **Discuss the anatomy of the urethral crest.** (6 points)

Part IV. Answer in the space provided (including the back of the page or the additional pages for each question). (36 pts)

1. A 44-yr-old male is catheterized following an automobile accident. As you place the catheter into the urethra, it ruptures the membranous urethra, pierces the superior fascia of the urogenital diaphragm, and urine and blood extravasate into the ischiorectal fossa.

Discuss the boundaries and contents of the ischiorectal fossa, fascial specializations, vascularization, innervation, lymphatic drainage, the relationship of the ischiorectal fossa to the superficial and deep pouches, and provide an explanation of your observation that urine does not accumulate in the superficial pouch. (12 pts).

EXAM NUMBER _____

EXAM NUMBER _____

2. A 45-yr old male is found to have cancer of the pancreas. Fortunately, the cancer is confined to the head of the pancreas, and you are planning on performing a Whipple procedure that will surgically remove this region. As a fellow in gastroenterology, you are requested to present a comprehensive review of the pancreas at morning rounds. **Indicate your understanding of the pancreas, providing, structure, vasculature, innervation, lymphatic drainage, relationships, and development.** (12 pts)

EXAM NUMBER _____

EXAM NUMBER _____

3. A 25-yr old female is rushed to the emergency room with a gun shot wound that enters through the anterior abdominal wall. In preparation for surgery, you review the anatomy of the anterior abdominal wall. **Discuss the organization of the anterior abdominal wall, and include muscles, ligaments, fascia, fascial specializations, nerves, and vascular supply.** (12 pts)

EXAM NUMBER _____

EXAM NUMBER _____