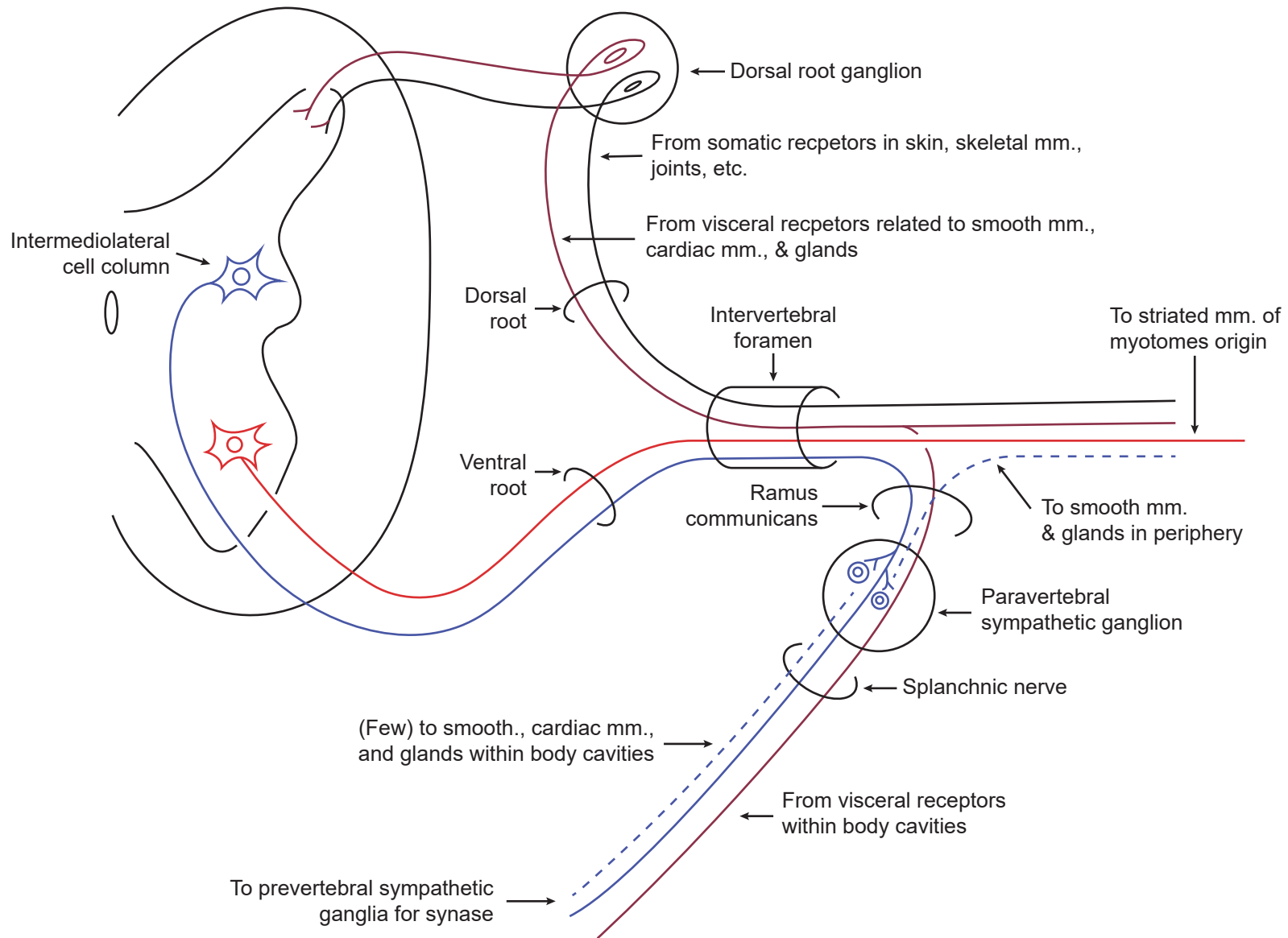


"Typical" spinal nerve (i.e. T1-L2)*

GSA GVE GSE GVA



*Above and below these levels, preganglionic GVE sympathetic contribution (solid blue) is absent; postganglionic sympathetic fibers (dotted blue) enter segmental nerves from sympathetic ganglia (via communicating rami) at all levels. Only a few postganglionic fibers are to be found in any splanchnic nerve; preganglionic fibers are the major efferent component.