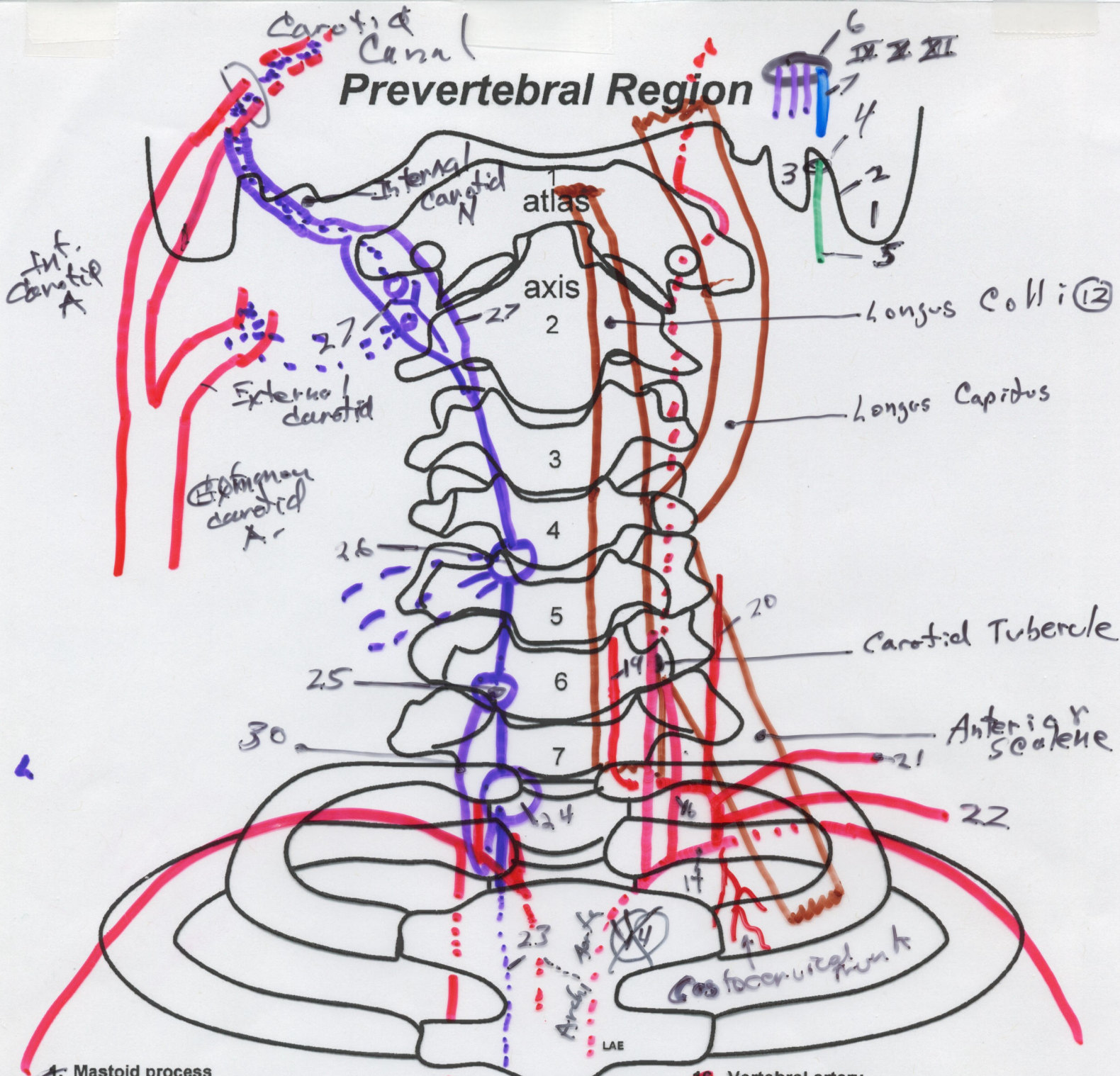


Prevertebral Region



- 1. Mastoid process
- 2. Groove for posterior belly digastric
- 3. Styloid process
- 4. Stylomastoid foramen
- 5. Facial nerve
- 6. Jugular foramen
- 7. Internal jugular vein
- 8. Glossopharyngeal nerve (CN IX)
- 9. Vagus nerve (CN X)
- 10. Spinal accessory nerve (CN XI)
- 11. Hypoglossal nerve (CNXII)
- 12. Longus colli muscle
- 13. Longus capitus muscle
- 14. Subclavian artery
- 15. Common carotid artery

- 16. Vertebral artery
- 17. Transverse foramen of atlas
- 18. Thyrocervical trunk
- 19. Inferior thyroid artery
- 20. Ascending cervical artery
- 21. Transverse cervical artery
- 22. Suprascapula artery
- 23. Thoracic sympathetic trunk
- 24. Stellate ganglion
- 25. Vertebral cervical sympathetic ganglion
- 26. Middle cervical sympathetic ganglion
- 27. Superior cervical sympsathetic ganglion
- 28. Internal carotid artery
- 29. Internal carotid nerve and plexus
- 30. Ansa subclavia

Internal
Thoracic
A.