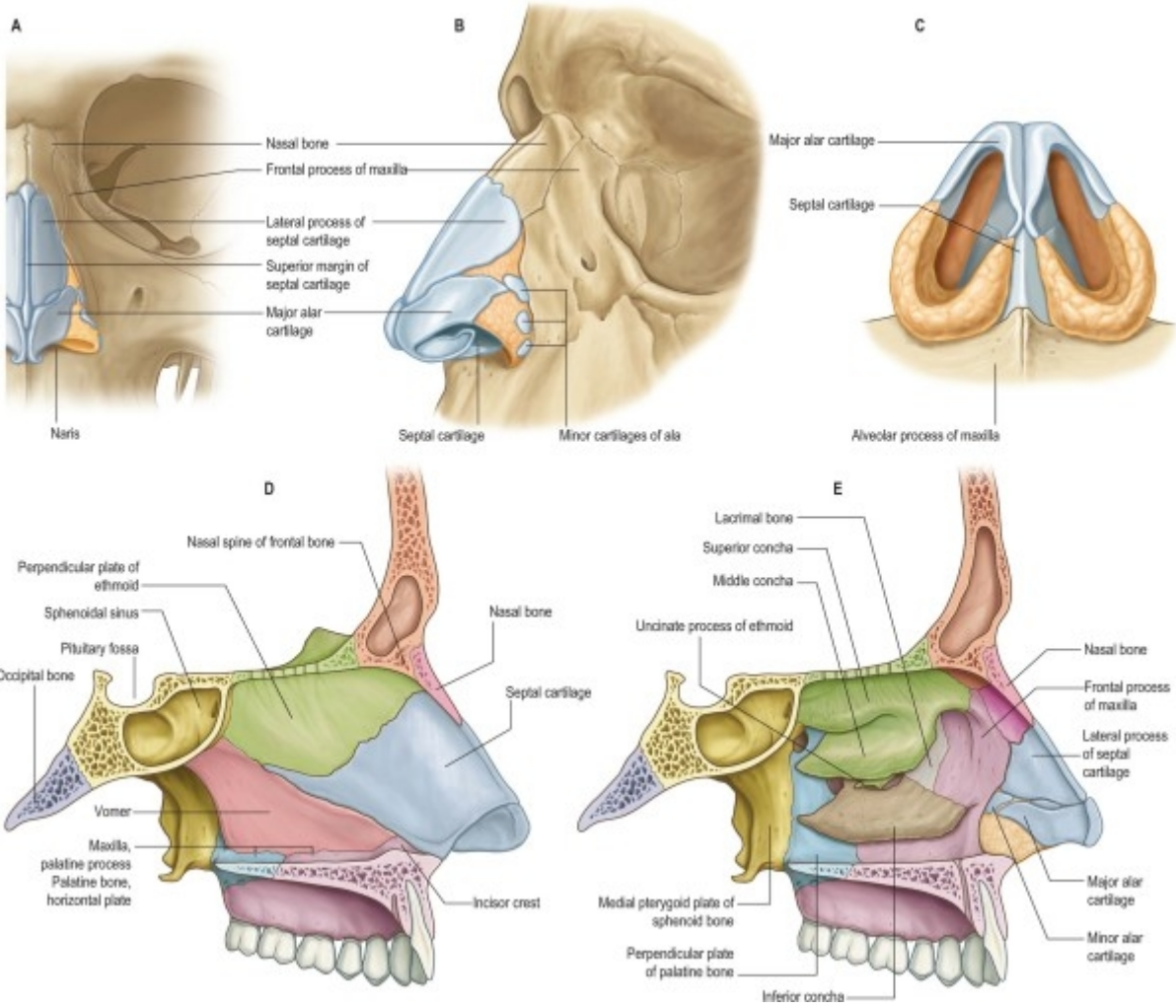
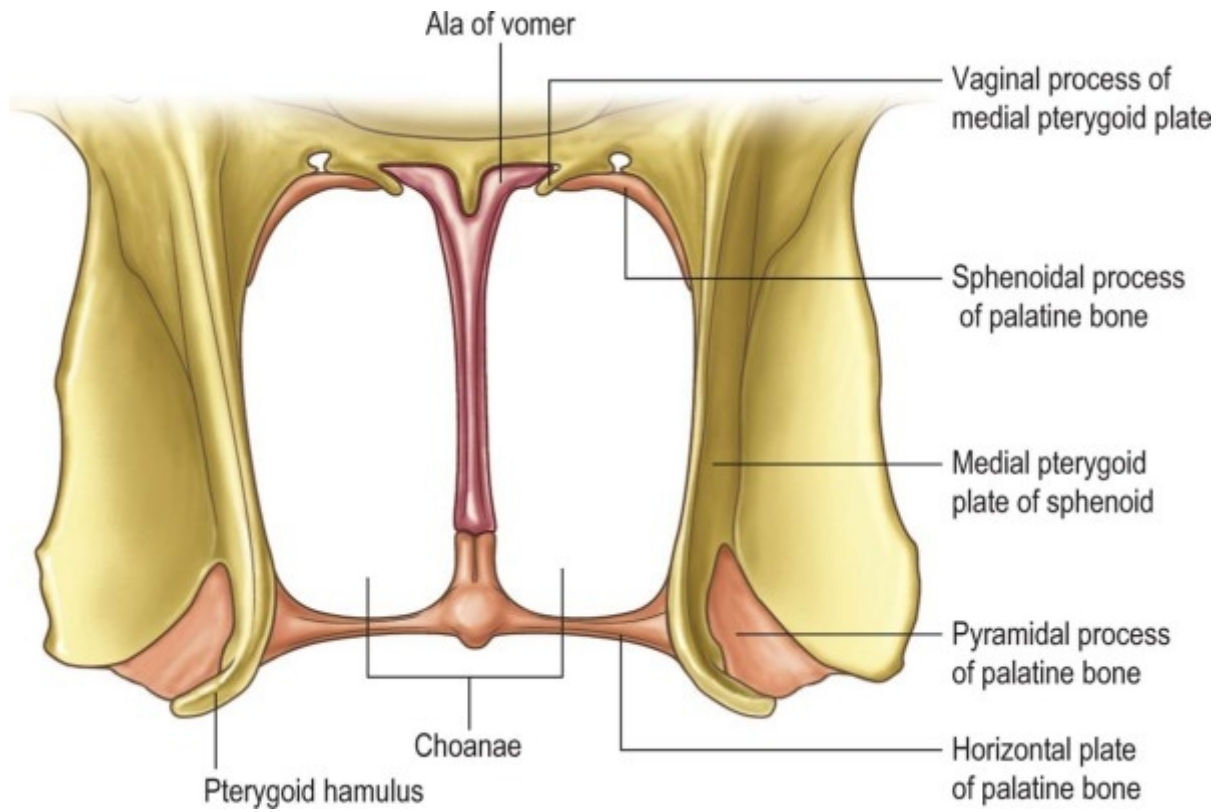


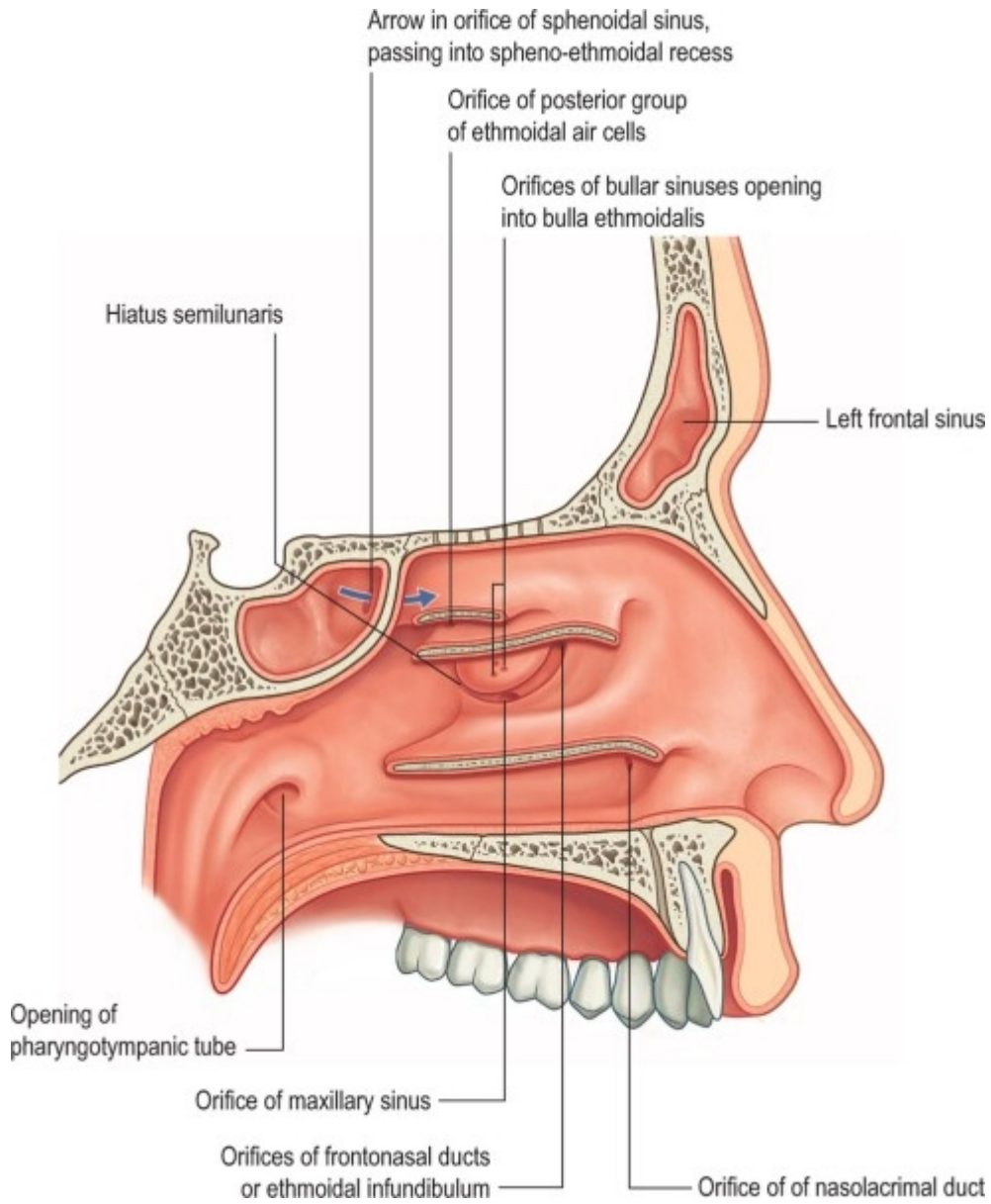
# Bones and Cartilage of the Nose 32.2



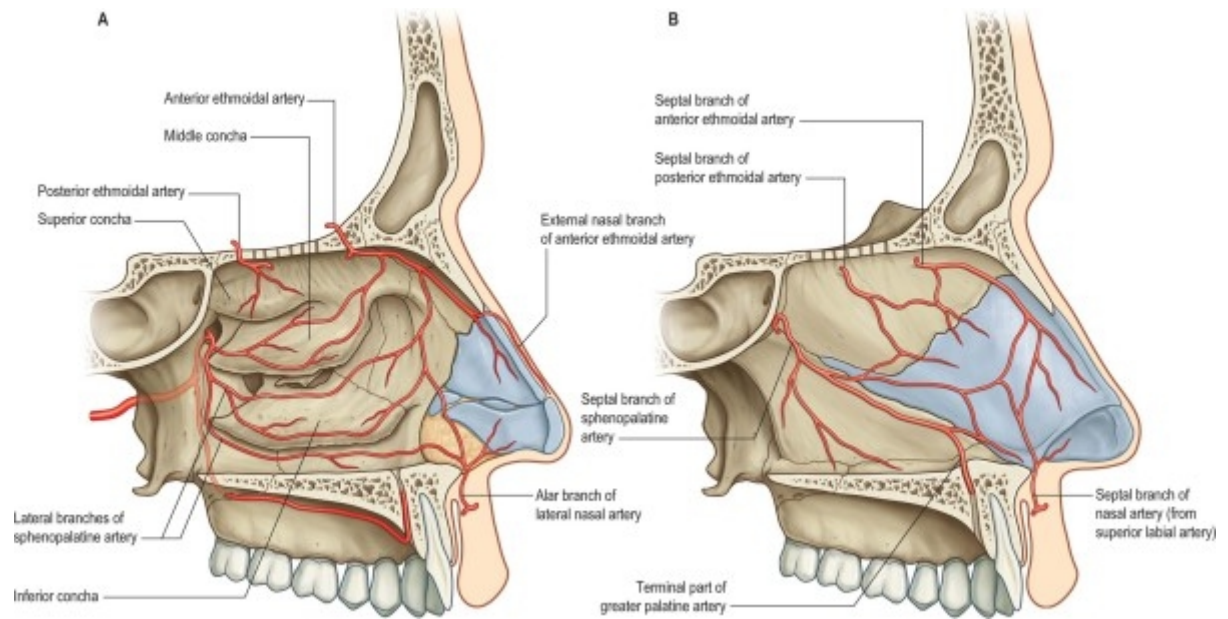
## Posterior View of the Choanae 32.4



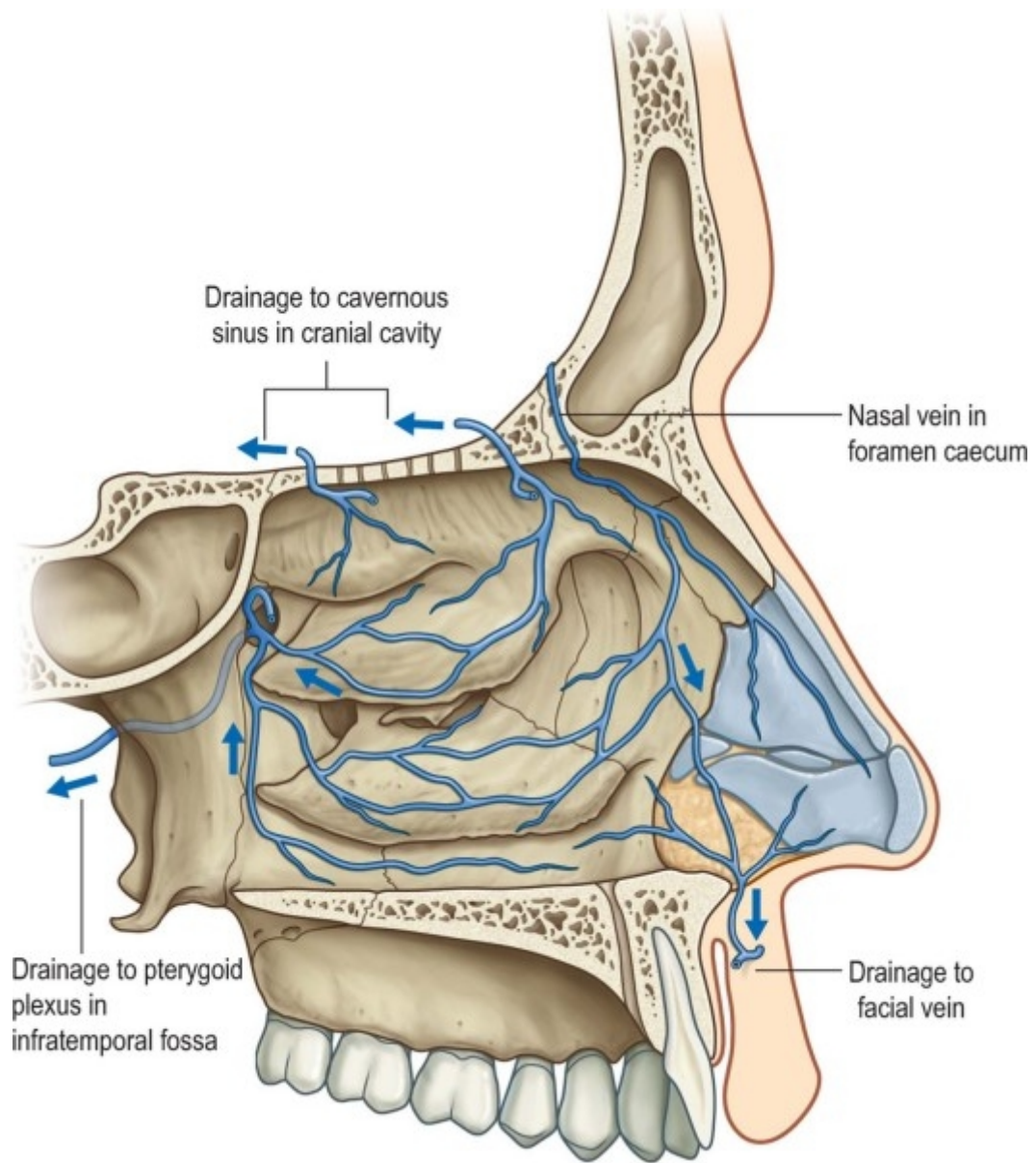
# Lateral Nasal Wall 32.5



# Arteries of the Nasal Cavity 32.7



# Veins of the Lateral Nasal Wall 32.8



# Nerves of the Nasal Cavity 32.9

