

EXAMINATION 5

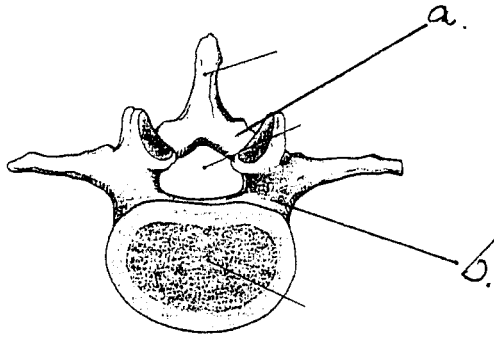
October 7, 2005

**PART I. Answer in the space provided. (6 pts)**

1. Identify the structures. ( 1 pt)

a. \_\_\_\_\_

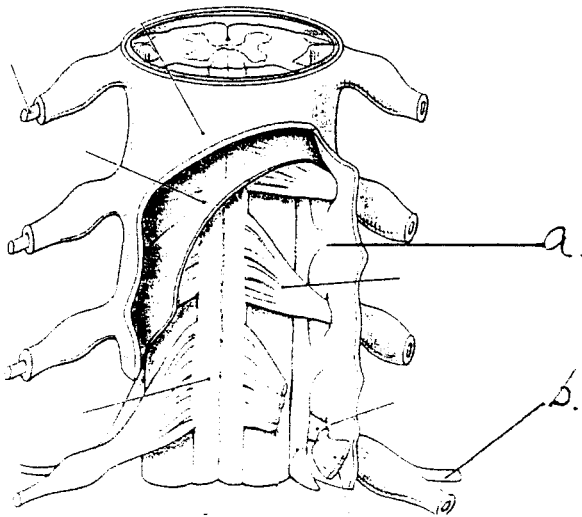
b. \_\_\_\_\_



2. Identify the structures. (1 pt)

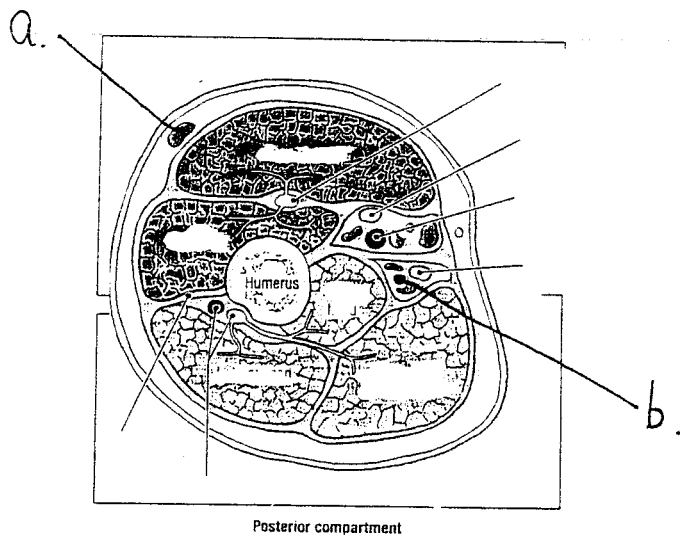
a. \_\_\_\_\_

b. \_\_\_\_\_



a. \_\_\_\_\_

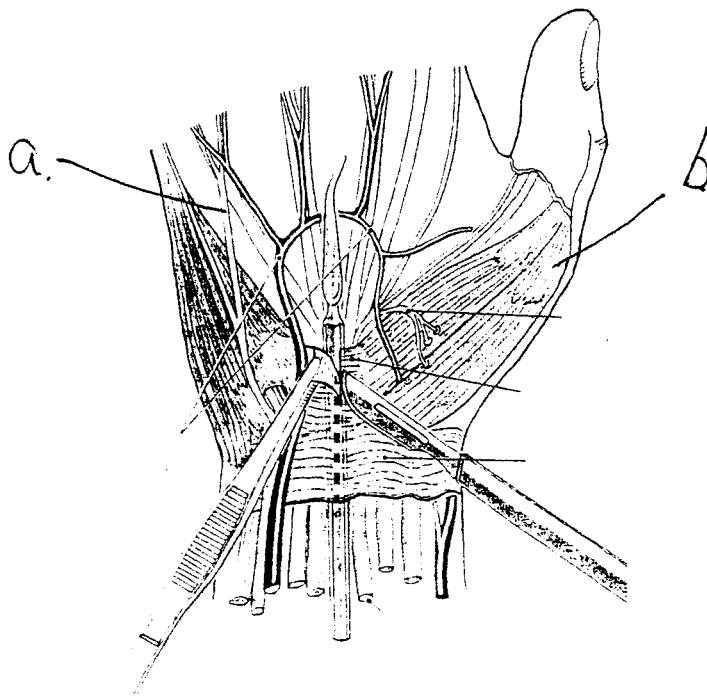
b. \_\_\_\_\_



4. Identify the structure. (1 pts)

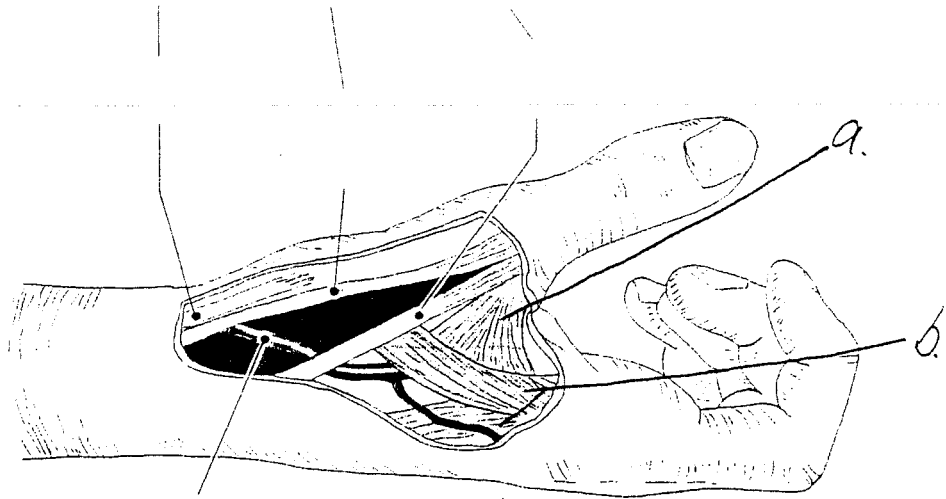
a. \_\_\_\_\_

b. \_\_\_\_\_



a. \_\_\_\_\_

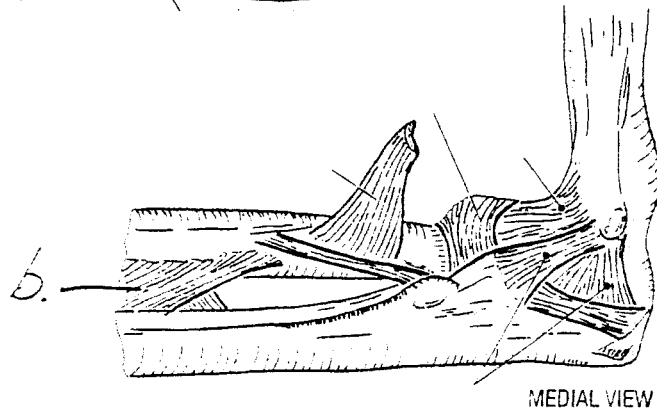
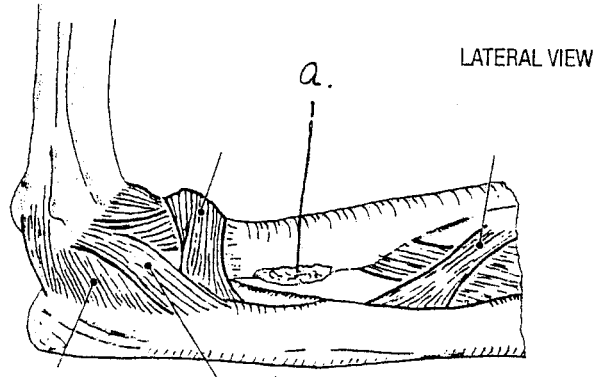
b. \_\_\_\_\_



6. Identify the structures. (1 pt)

a. \_\_\_\_\_

b. \_\_\_\_\_



1. With respect to the development of muscles, bones, and limbs:

- a. Muscles are of endodermal origin.
- b. The skeletal system develops from paraxial and lateral plate mesoderm and from neural crest.
- c. Fingers and toes are formed when cell death in the apical ectodermal ridge occurs.
- d. Skeletal muscle is derived from paraxial mesoderm.
- e. The upper limb rotates 90 degrees laterally, so that the extensor muscles lie on the lateral and posterior surface and the thumbs lie laterally.
- f. The lower limb rotates approximately 90 degrees medially, placing the extensor muscles on the anterior surface and the big toe medially.
- g. Limb buds become visible as outpocketings from ventrolateral body wall at the end of the 8th week.
- h. The most sensitive period for teratogen-induced limb malformations is the 4th and 5th weeks of development.

2. With regard to the back region:

- a. The axial musculature is innervated by ventral rami.
- b. The serratus posterior inferior mediates exhalation.
- c. The serratus posterior superior retracts the scapula
- d. The dorsal scapular nerve crosses medial to the levator scapula muscle.
- e. The suprascapular nerve passes superior to the superior transverse scapular ligament.
- f. The spinal accessory nerve crosses lateral to the levator scapula muscle.
- g. The semispinalis capitus muscle contributes to the anterior boundary of the suboccipital triangle.
- h. The thoracolumbar fascia contributes to the origin of the latissimus dorsi muscle.

- a. The greater occipital nerve provides motor innervation to the muscles that compose the boundaries of the suboccipital triangle.
- b. The obliquus capitus inferior muscle rotates the atlantooccipital joint.
- c. The rectus capitus posterior <sup>major</sup> muscle acts to flex the atlantooccipital joint
- d. The transverse foramina of the atlas and axis transmit the vertebral artery.
- e. The obliquus capitus superior muscle takes origin from the superior nuchal line
- f. The vertebral artery passes through the posterior atlantooccipital membrane.
- g. The suboccipital nerve crosses the superior nuchal line medial to the occipital artery
- h. The greater occipital nerve leaves the suboccipital region by passing posterior to the obliquus capitus inferior muscle.
- i. The spine of the axis is bifid whereas the atlas has a tubercle in place of a spine
- j. The rectus capitus posterior major muscle crosses both the atlantooccipital joint and the atlantoaxial joint.

4. With regard to the scapular region:

- b. The infraspinous fossa is the site of the acromial anastomosis.
- c. The omohyoid muscle is lateral to the superior transverse scapular ligament.
- d. Ligation (occlusion, blockage) of the 2<sup>nd</sup> part of the axillary artery causes reverse blood flow in the suprascapular artery.
- e. The upper fibers of the trapezius muscle insert lateral on the scapular spine
- f. The serratus anterior muscle assists the trapezius muscle in mediating upward rotation of the scapula
- g. The coracoid process provides for the insertion of the coracobrachialis and the origin of the pectoralis minor.

5. With regard to the axilla and brachial plexus

- a. The cords of the brachial plexus are named based on their position around the second part of the axillary artery.
- b. The axillary artery begins as the continuation of the subclavian artery at the upper border of the third rib.

- d. The suprascapular nerve arises from the upper trunk of the brachial plexus.
  - e. The medial cord is the direct continuation of the anterior division of the lower trunk.
  - f. The long thoracic nerve arises from the posterior cord of the brachial plexus.
  - g. The axillary nerve provides motor input to the deltoid and teres minor muscles
  - h. Complete lesions of the musculocutaneous and median nerves within the axilla will cause total loss of flexion at the elbow joint.
  - i. A lesion of the posterior cord involving all of its branches will cause total loss of medial rotation at the glenohumeral joint.
  - j. Complete lesions of the ulnar, median, radial, and musculocutaneous nerves within the axilla will cause total loss of flexion at the elbow.
6. With regard to the anterior compartment of the arm:
- a. All flexors in the anterior compartment of the arm are innervated by the musculocutaneous nerve.
  - b. The brachialis muscle assists the biceps brachii in flexing the arm.
  - c. The brachial artery begins lateral to the median nerve in the upper arm and then crosses to the medial side of the ~~brachial artery~~ **median nerve** as it approaches the cubital fossa.
  - d. The lateral antebrachial cutaneous nerve can be found crossing the anterior surface of the brachialis muscle and the posterior surface of the biceps brachii muscle.
  - e. The coracobrachialis muscle contributes to the range of abduction from 125 degrees to approximately 145 degrees.
  - f. The inferior ulnar collateral artery crosses anterior to the axis of the elbow joint.
7. With regard to the posterior compartment of the arm:
- a. The anterior boundary of the triangular space is, in part, formed by the spiral (radial) groove of the humerus.
  - b. The ascending branch of the profunda brachii artery participates in an anastomosis with the posterior humeral circumflex artery.
  - c. The lateral head of the triceps brachii originates superior and lateral to the spiral groove, whereas the medial head of the triceps brachii originates medial and inferior to the spiral groove.

- e. The deep radial nerve innervates the anconeus muscle.
  - f. The radial collateral artery pierces the lateral intermuscular septum.
  - g. A complete lesion of the radial nerve at the spiral (radial) groove causes loss of extension at the elbow.
  - h. A complete lesion of the radial nerve at the spiral (radial) groove causes "wrist drop."
8. With regard to the anterior compartment of the forearm:
- a. The ulnar nerve passes between the two heads of origin of the flexor carpi ulnaris muscle
  - b. The pronator teres has a humeral head of origin and a radial head of origin
  - c. A complete lesion of the ulnar nerve at the ulnar groove would cause loss of flexion of the distal interphalangeal joint for the lateral two digits.
  - d. A complete lesion of the ulnar nerve at the ulnar groove would cause the wrist joint to be partially extended and partially abducted (radially deviated).
  - e. A complete lesion of the ulnar nerve at the ulnar groove will weaken abduction of the little finger.
  - f. A complete lesion of the median nerve superior to the cubital fossa will weaken flexion at the elbow joint.
  - g. A complete lesion of the median nerve superior to the cubital fossa would cause the wrist to be partially extended and partially adducted (ulnar deviated).
  - h. The anterior interosseous nerve and artery pierce the distal interosseous membrane to enter the posterior compartment.
9. With regard to the posterior compartment of the forearm:
- a. The posterior interosseous nerve and the anterior interosseous artery travel along the posterior surface of the distal interosseous membrane.
  - b. The deep radial nerve innervates all muscles in the posterior compartment of the forearm.
  - c. The deep radial nerve is applied to the bony surface of the radius as it travels from the cubital fossa to the posterior compartment of the arm.
  - d. The radial nerve innervates the supinator muscle.

- f. A complete lesion of the deep radial nerve causes "wrist drop."
  - g. The interosseous recurrent artery lies deep to the anconeus muscle and forms an anastomosis with the middle collateral artery.
  - h. The posterior interosseous artery circles the lateral aspect of the radius in close proximity to the posterior interosseous nerve.
10. With regard to the dorsum of the hand:
- a. The tendon of the extensor indicis muscle is anterior (palmar) to the tendon of the extensor digitorum muscle.
  - b. The deep radial nerve innervates the extensor digitorum brevis prior to providing sensation between the second and third digits.
  - c. The dorsal interosseous muscles are bipennate (have two heads of origin with a central tendon).
  - d. Independent movement of the digits during extension is partly due to intertendinous slips.
  - e. The superficial radial nerve provides sensation to the nail beds of the radial 2 fingers.
  - f. The index finger has two dorsal interosseous muscles inserting onto the extensor hood.
  - g. The interosseous muscles attach to the extensor hood distal to the attachments of the lumbricals.
  - h. The superficial radial nerve travels from the anterior forearm to the dorsum of the hand by passing deep to the tendon of the extensor pollicis brevis.



1. Define the boundaries, contents, relationships, and importance of the cubital fossa. (6 pts)





1. Review the anatomy and stability of the glenohumeral (shoulder) joint. Include bones, articular surfaces, cavities, capsules, contents, muscles, movements and limitations of movement, vascularization, innervation, relationships, and lymphatic drainage. Include mention of shoulder dislocations and nerve injury. (12 pts).

... and the spinal canal. Include bones, articulations, ligaments, spaces, contents, muscles (omit detailed accounts of transversospinalis muscles), movements and limitations of movement, vascularization, innervation, relationships, and lymphatic drainage. Include mention of the anterior displacement of the L5 vertebra relative to the S1 vertebra in nerve injuries. Include mention of the fascial layers penetrated during lumbar puncture (spinal tap). (12 pts)

movements, independence of movement, limitations of movement, vascularization, innervation, relationships, and lymphatic drainage. Include mention of compression injury to the hamate in nerve injuries. (12 pts)