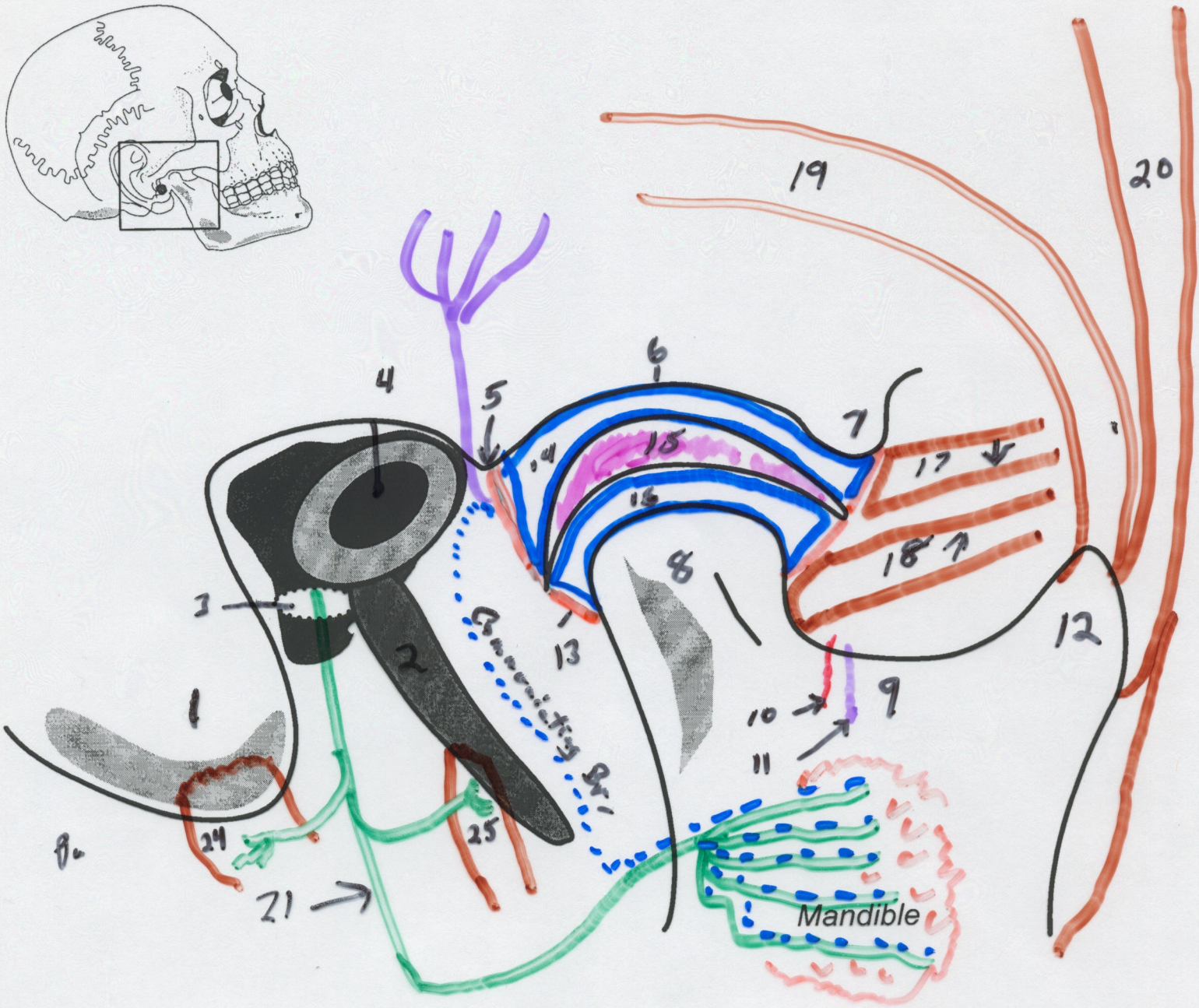
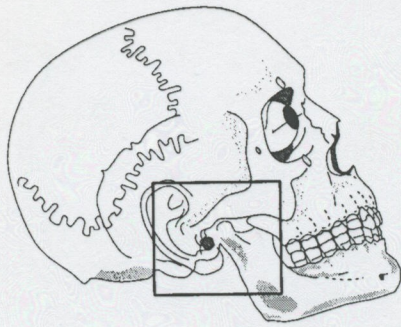


Temporomandibular Joint



- | | |
|------------------------------|---|
| 1. Mastoid process | 15. Articular Disk |
| 2. Styloid process | 16. Inferior synovial cavity |
| 3. Stylomastoid foramen | 17. Superior head of lateral pterygoid |
| 4. External acoustic meatus | 18. Inferior head of lateral pterygoid |
| 5. Postglenoid tubercle | 19. Posterior fibers of temporalis |
| 6. Mandibular fossa | 20. Anterior fibers of temporalis |
| 7. Articular tubercle | 21. Facial nerve |
| 8. Condyle | 22. Auriculotemporal nerve |
| 9. Mandibular notch | 23. Communicating branch (parasympathetics) |
| 10. Masseteric artery | 24. Posterior belly digastric |
| 11. Masseteric nerve | 25. Stylohyoid muscle |
| 12. Coronoid process | 26. Lesser occipital nerve |
| 13. Articular capsule | 27. Great auricular nerve |
| 14. Superior synovial cavity | 28. Parotid Gland |